



DERMATOLOJİDE & KOZMETOLOJİDE GELİŞMELER KONGRESİ 2023

23-27 MAYIS 2023

CORNELIA DIAMOND GOLF RESORT OTEL, ANTALYA



İnflamatuvar Deri Hastalıklarında Dermatoskopi

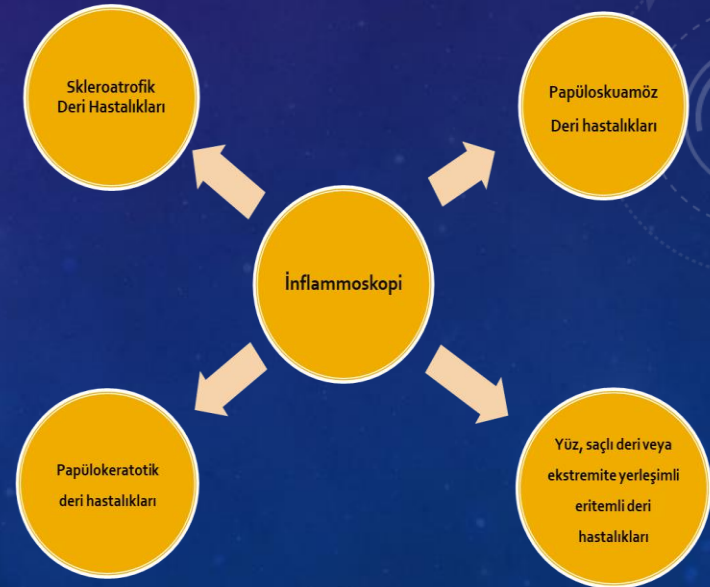
Doç. Dr. Tuğba Kevser Uzunçakmak
İstanbul Üniversitesi- Cerrahpaşa, Cerrahpaşa Tıp Fakültesi
Deri ve Zührevi Hastalıkları Anabilim Dalı
26.05.2023

SUNUM PLANI

- İnflamatuar deri hastalıklarında temel dermatoskopik paternler
- Papüloskuamöz hastalıklarda dermatoskopi
- Papülokeratotik hastalıklarda dermatoskopi
- Skleroatrofik hastalıklarda dermatoskopi
- Yüz yerleşimli inflamatuvar hastalıklarda dermatoskopi

İnflamatuvar deri hastalıklarında dermatoskopi

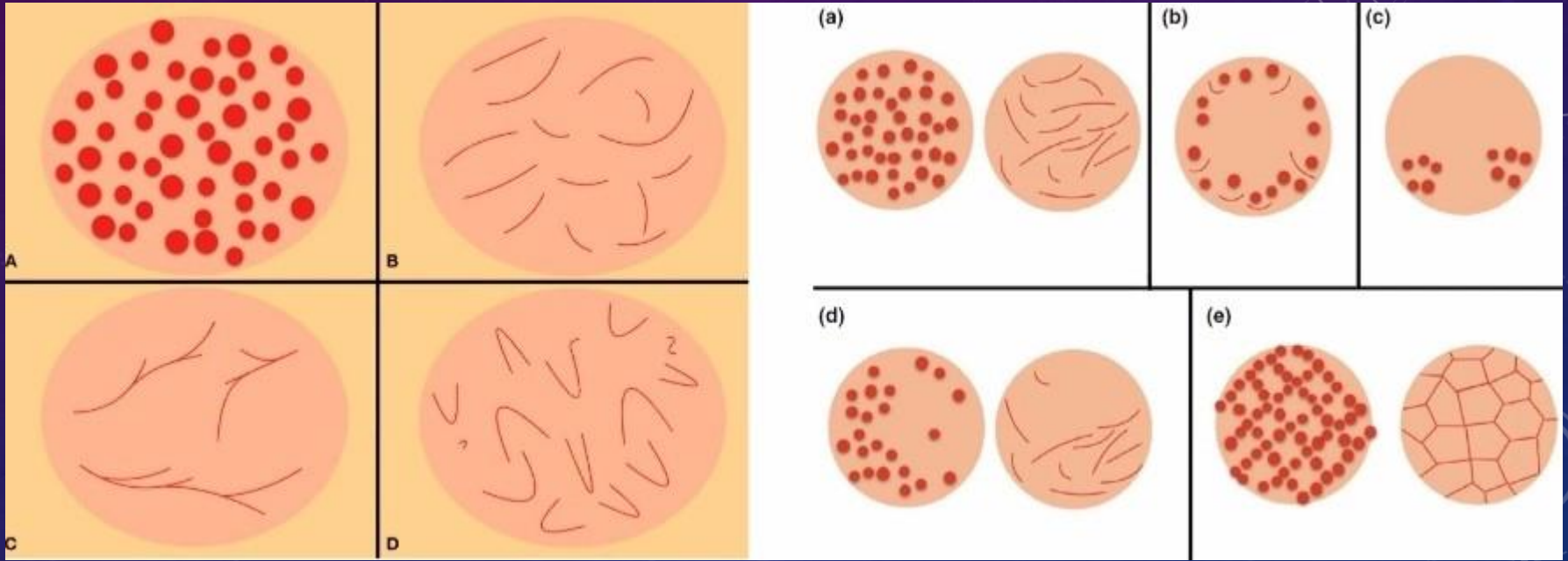
- 2000 genel dermatolojide kullanım, inflammoskopi (inflammoscopy)
- İnflamatuvar deri hastalıklarının tanı , ayırıcı tanısı ve tedavi takibinde
- Klinik bulgular, histopatolojik korelasyon



Beş Temel Dermatoskopik Özellik


1. Damar yapıları (morfoloji ve dağılım)
2. Skuam yapısı (renk ve dağılım)
3. Foliküler bulgular
4. Diğer ipuçları (zemin özellikleri vb)
5. Spesifik ipuçları (tanıya özgü, dermatopatolojik korelasyon)

VASKÜLER YAPILAR



- Morfolojik özelliklerine göre noktasal, lineer (irregüler veya serpijinöz) , virgül şeklinde, kıvrımlı lineer firkete (loop damarlar), glomerüler, arborizan damarlar
- Dağılımlarına göre uniform, düzenli, düzensiz, kümesel, radyal, retiküler veya dallanan damarlar
- Koyu tenli hastalarda vasküler yapılar net görülemeyebilir
- Hiperkeratotik ve ekskoriye lezyonlarda vasküler yapılar seçilemeyebilir.

SKUAMLARIN RENGİ



- Beyaz skuamalar “kuru” dermatozlarda tipik
- Sarı skuamalar serum ekstrevasyonu izlenen dermatozlarda tipik
- Kahverengi & siyah skuamalar keratin ve ekzojen/endojen pigment birikiminde (kir/melanin)

SKUAMLARIN YERLEŐİMİ

Difüz



Periferal

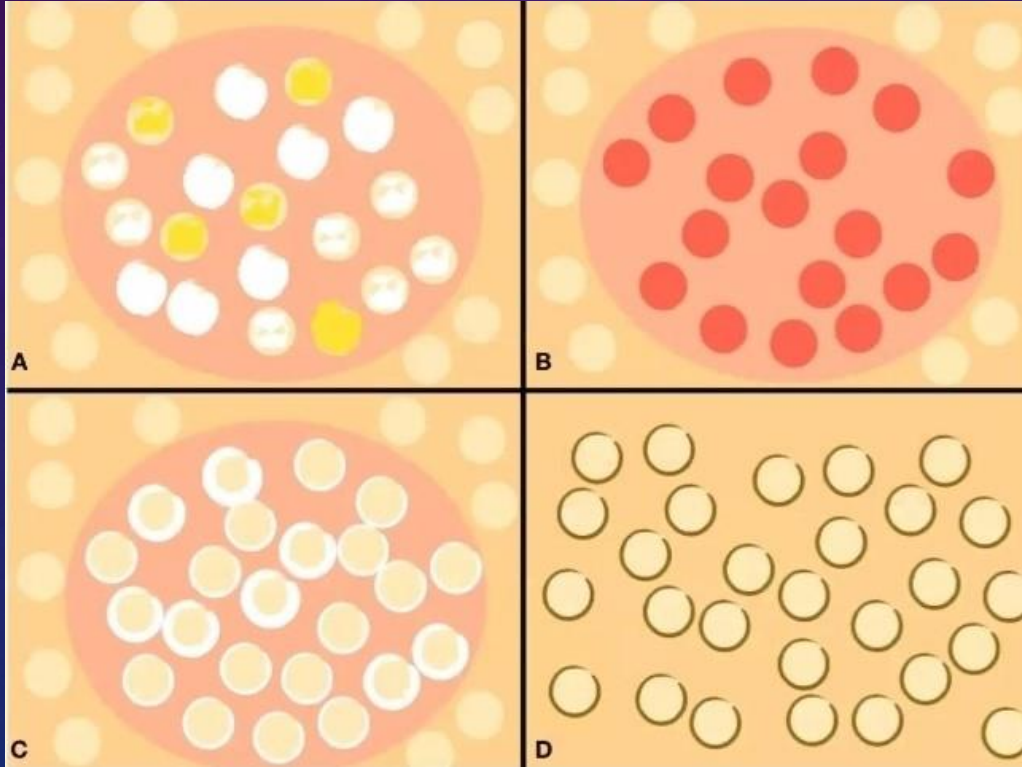
Merkezi



Dađınık/yama
tipi

FOLİKÜLER YAPILAR

Foliküler tıkaçlar
(foliküler açıklıkları
tıkayan beyaz/sarı
keratin yapılar)



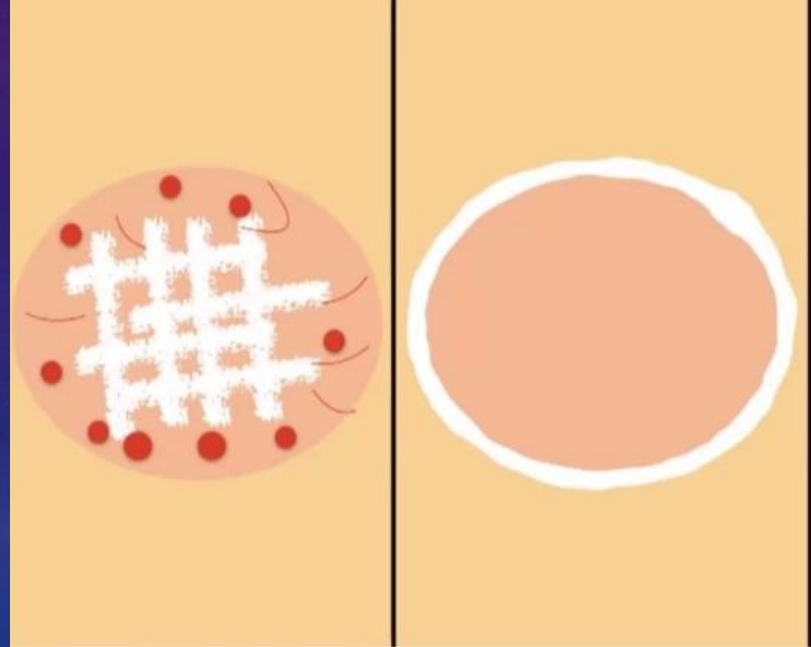
Perifoliküler beyaz
halo/depigmentasyon

Foliküler kırmızı
noktalar
Perifoliküler
inflamasyon

Perifoliküler
pigmentasyon

SPESİFİK BULGULAR

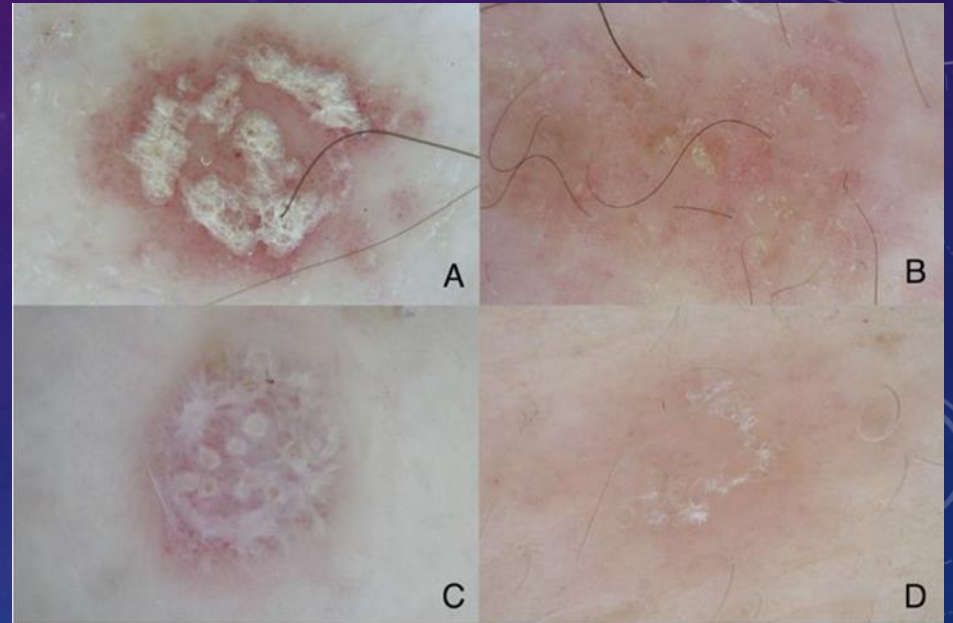
- Belli bir tanıya kuvvetli işaret eden bulgular
- Spesifik histopatolojik korelasyon



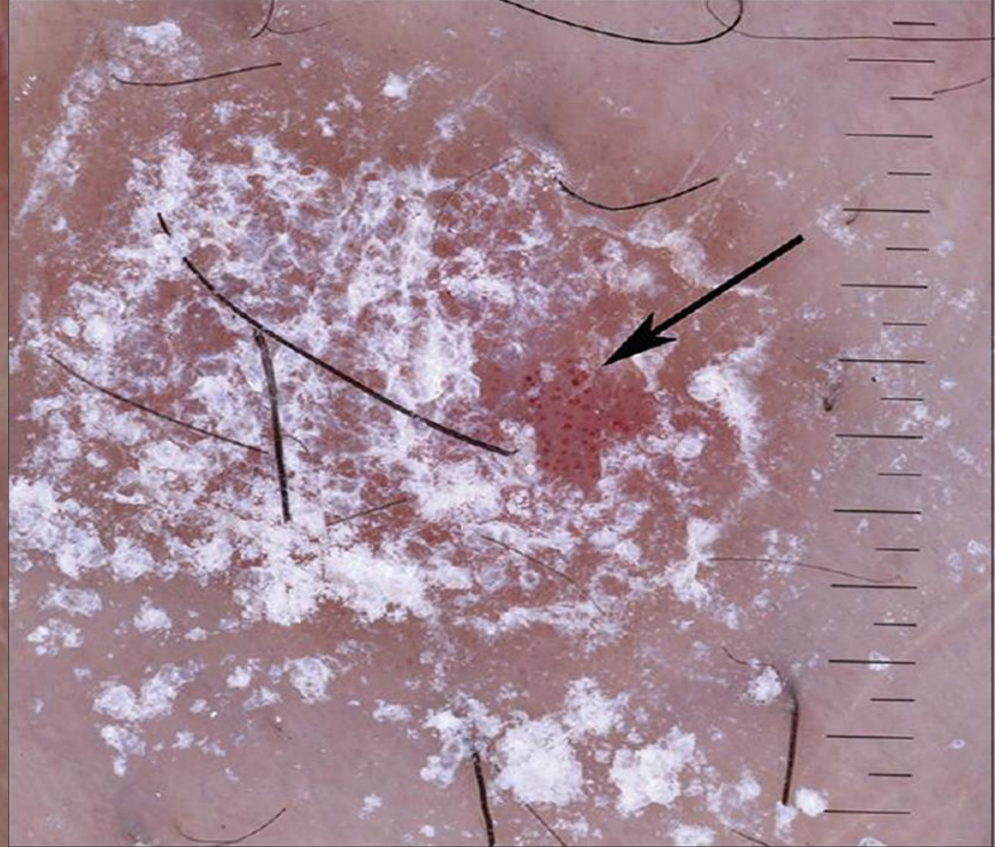
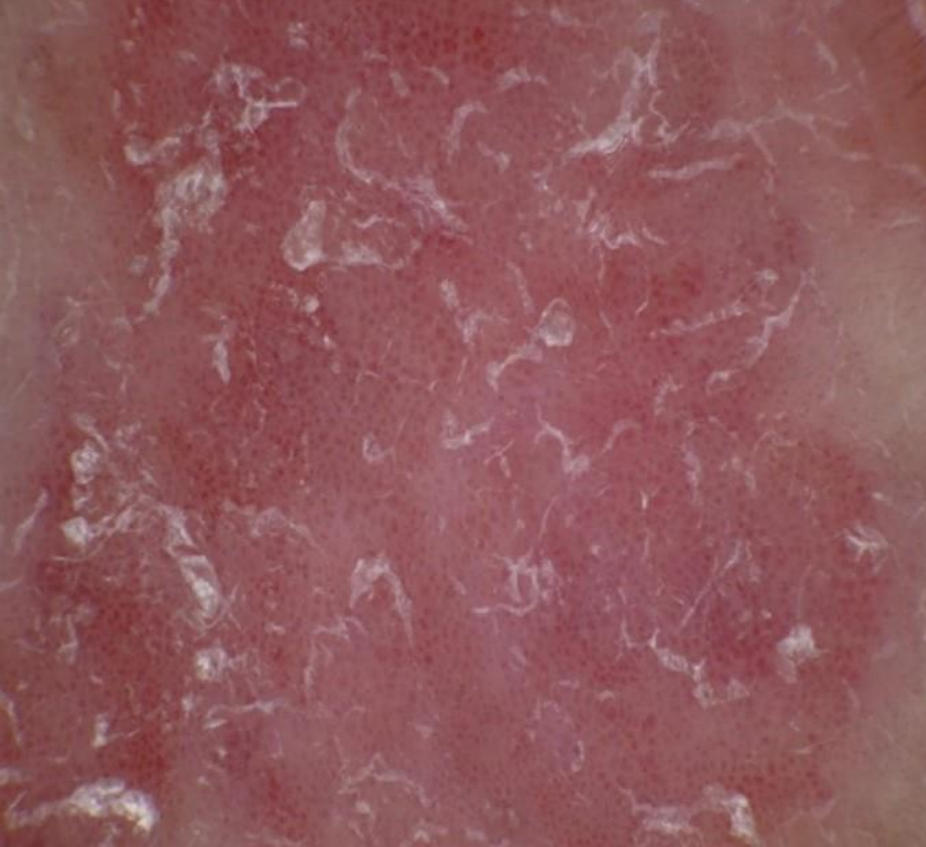
Papüloskuamöz Deri Hastalıklarında Dermatoskopi

Papüloskuamöz Deri Hastalıkları

- Psoriasis
- Dermatit
- Liken Planus
- Pityriazis likenoides kronika
- Pityriazis rosea
- Pityriazis rubra pilaris



Psoriasis



- Açık kırmızı pembe zemin
- Papiller dermisteki dilate kapilleri yansıtan düzenli noktasal damarlar, kanama odakları
- Difüz beyaz skuamlar (hiperkeratoz)

Ayırıcı Tanıda Dermataskopi



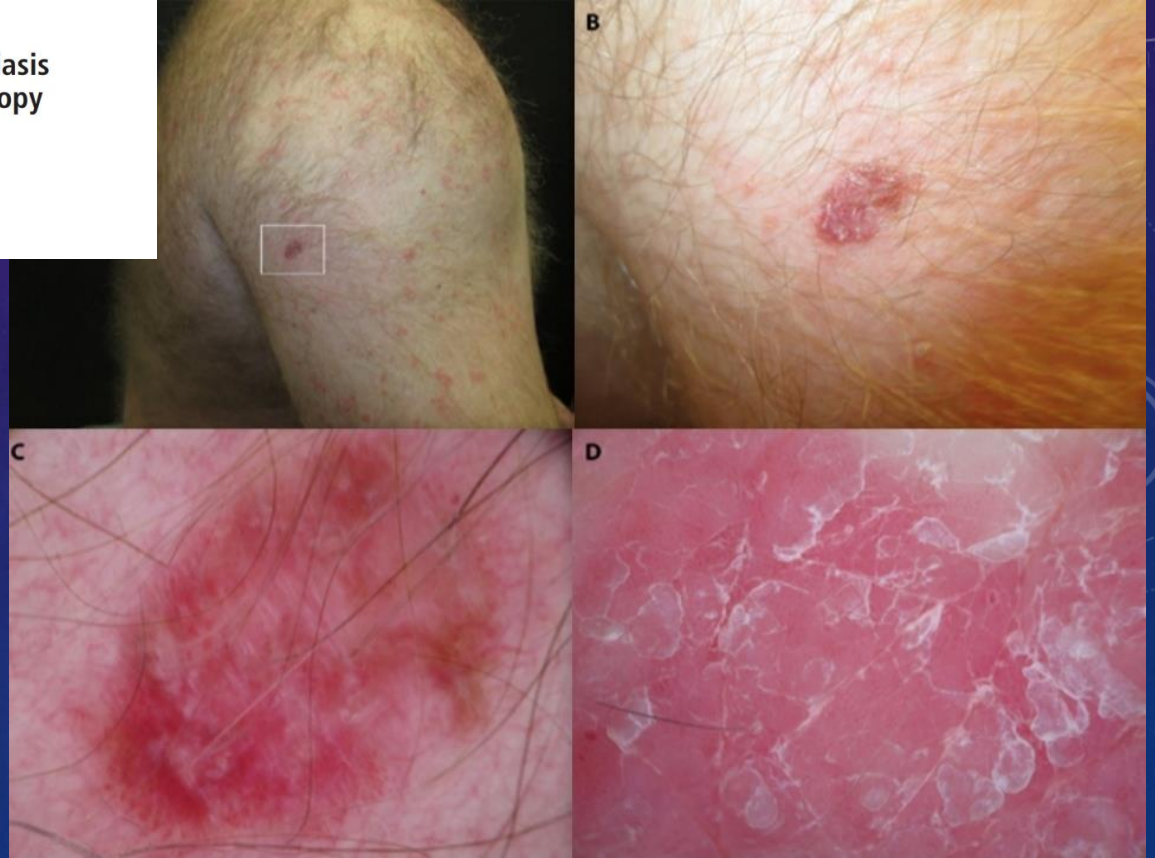
Dermatology Practical & Conceptual

A Case of Melanoma in a Patient With Psoriasis Highlighting the Importance of Dermatoscopy and Inflammoscopy

Sarah Benton¹, Lori Ann Fiessinger¹, Juan Pablo Jaimes¹

¹ Department of Dermatology, University of Minnesota Medical School, Minneapolis, Minnesota, USA

- Beyaz çizgiler
- Düzensiz dağılımda noktasal ve kıvrımlı damarlar



Tedavi Takibinde Dermatoskopi

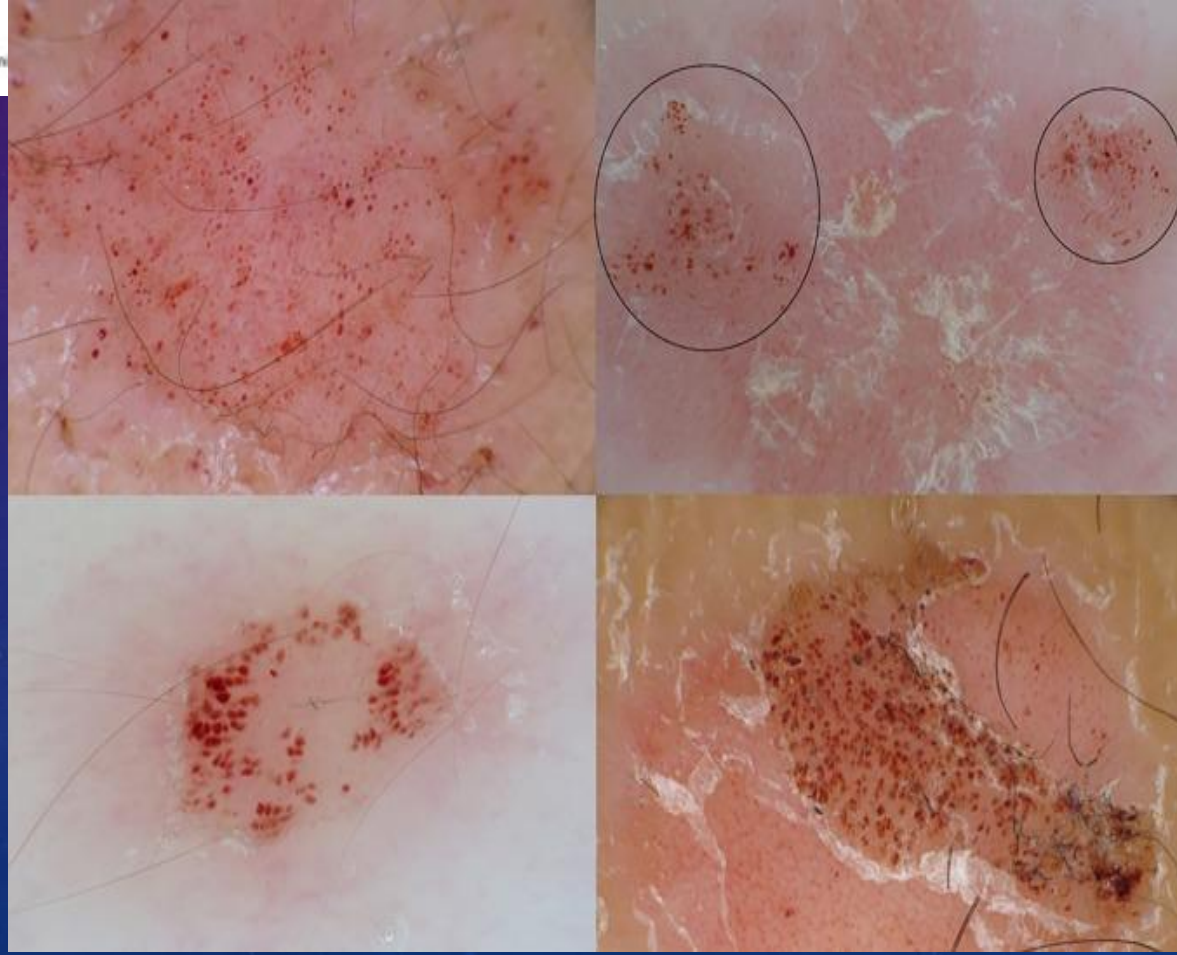
DERMATOLOGY PRACTICAL & CONCEPTUAL

www.derm101.com

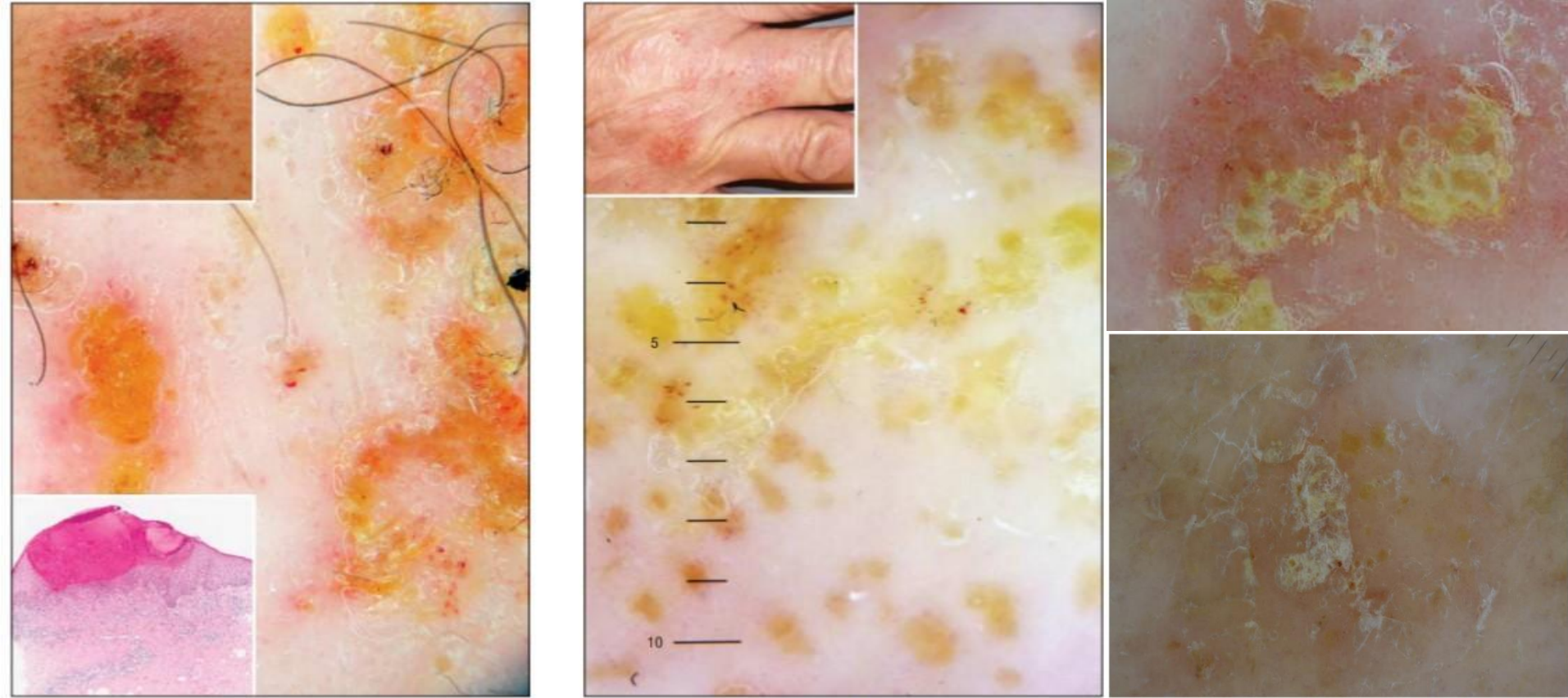
Dermoscopic hemorrhagic dots: an early predictor of response of psoriasis to biologic agents

Aimilios Lallas¹, Giuseppe Argenziano², Iria Zalaudek³, Zoe Apalla⁴, Marco Ardigo⁵, Patricia Chellini⁶, Natalia Coedeiro⁷, Mariana Guimaraes⁸, Athanasios Kyrgidis⁹, Elizabeth Lazaridou¹⁰, Caterina Longo¹¹, Elvira Moscarella¹², Ilias Papadimitriou¹³, Giovanni Pellacani¹⁴, Elena Sotiriou¹⁵, Efstratios Vakirlis¹⁶, Dimitrios Ioannides¹⁷

Tedavi yanıtını
gösteren bir
belirteç



Dermatit



- Sarı krut/kepek, sarı klod paterni
- Kırmızı- pembe zemin
- Düzensiz, lokalize dağılım gösteren noktasal damarlar, lineer damarlar, hemoraji

Ayırıcı Tanıda Dermataskopi

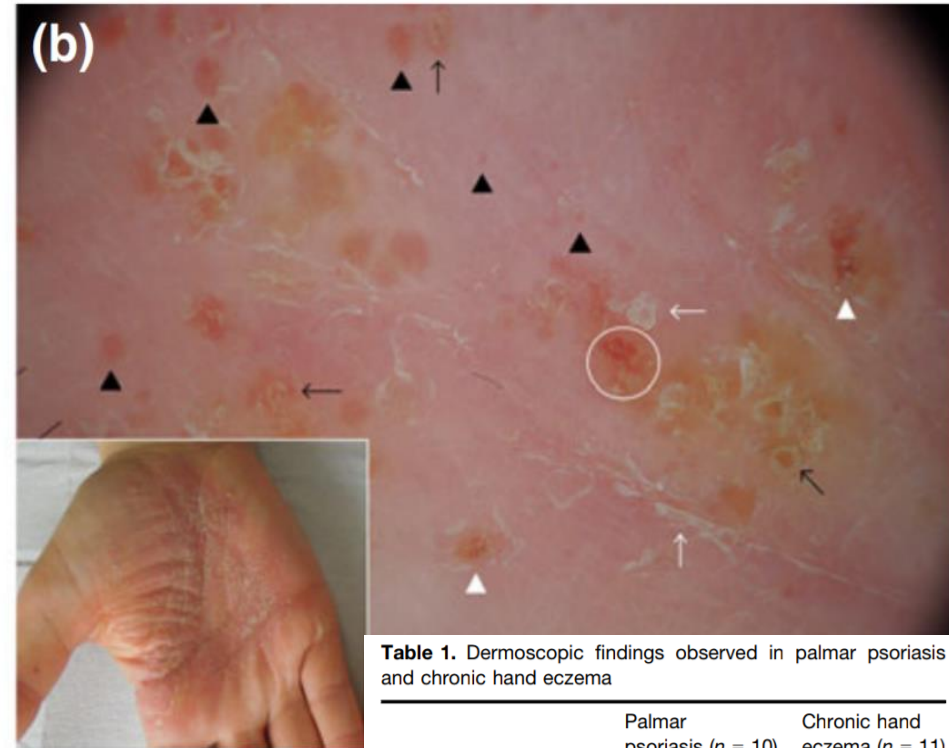
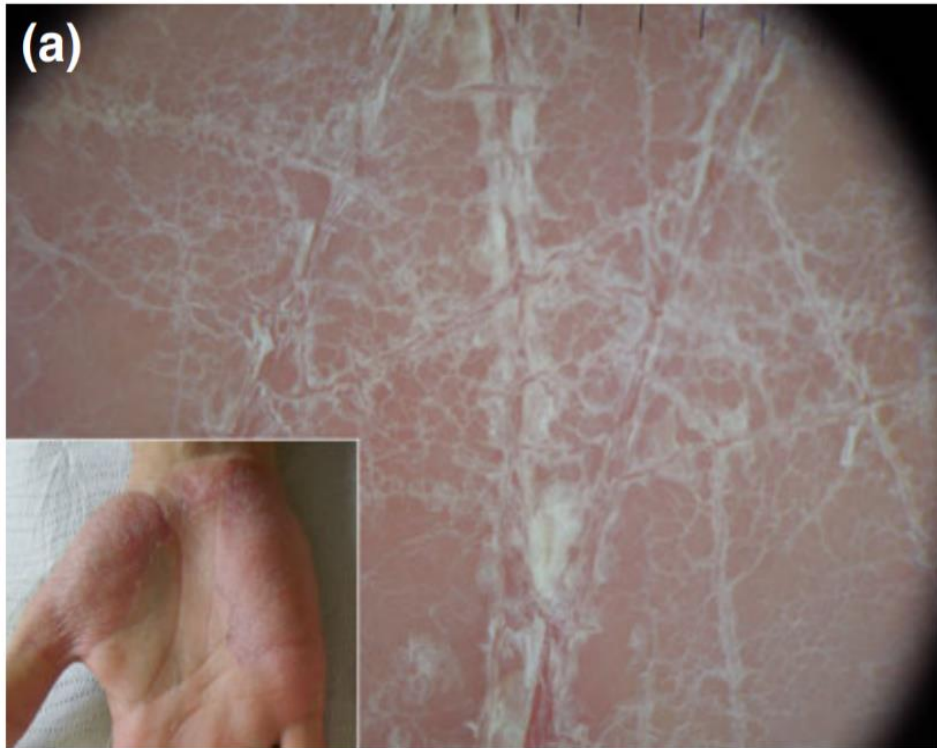
Table 1. Dermoscopic findings observed in palmar psoriasis and chronic hand eczema

| Dermoscopic finding | Palmar psoriasis (n = 10) n (%) | Chronic hand eczema (n = 11) n (%) |
|---------------------------------------|------------------------------------|---------------------------------------|
| Brownish-orange dots and/or globules* | 0 (0.0) | 8 (72.7) |
| Dotted vessels | 4 (40.0) | 3 (27.3) |
| Focal distribution | 0 (0.0) | 3 (27.3) |
| Diffuse distribution | 4 (40.0) | 0 (0.0) |
| White scales | 10 (100.0) | 5 (45.5) |
| Patchy distribution | 2 (20.0) | 5 (45.5) |
| Diffuse distribution* | 8 (80.0) | 0 (0.0) |
| Yellow scales* | 0 (0.0) | 10 (90.9) |
| Yellowish-orange crusts* | 0 (0.0) | 7 (63.6) |

* $P < 0.010$ between palmar psoriasis and chronic hand eczema.

- Sarı skuam yapısı
- Homojen olmayan yamasal dağılımda noktasal damarlar
- Kahverengi-turuncu nokta ve globüller

Pityriasis Likenoides

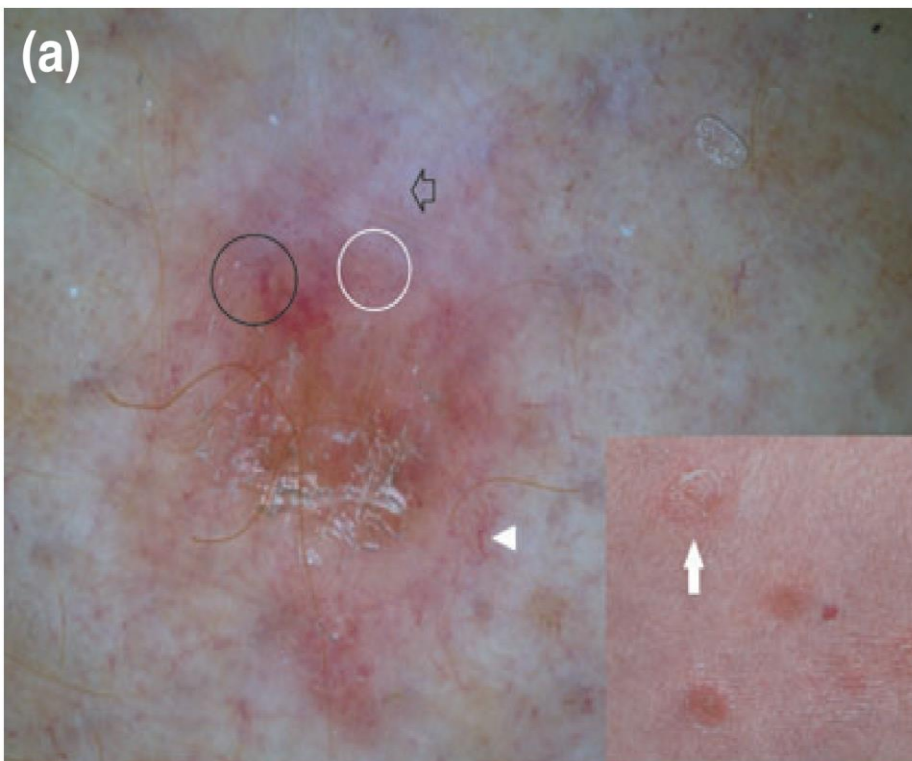
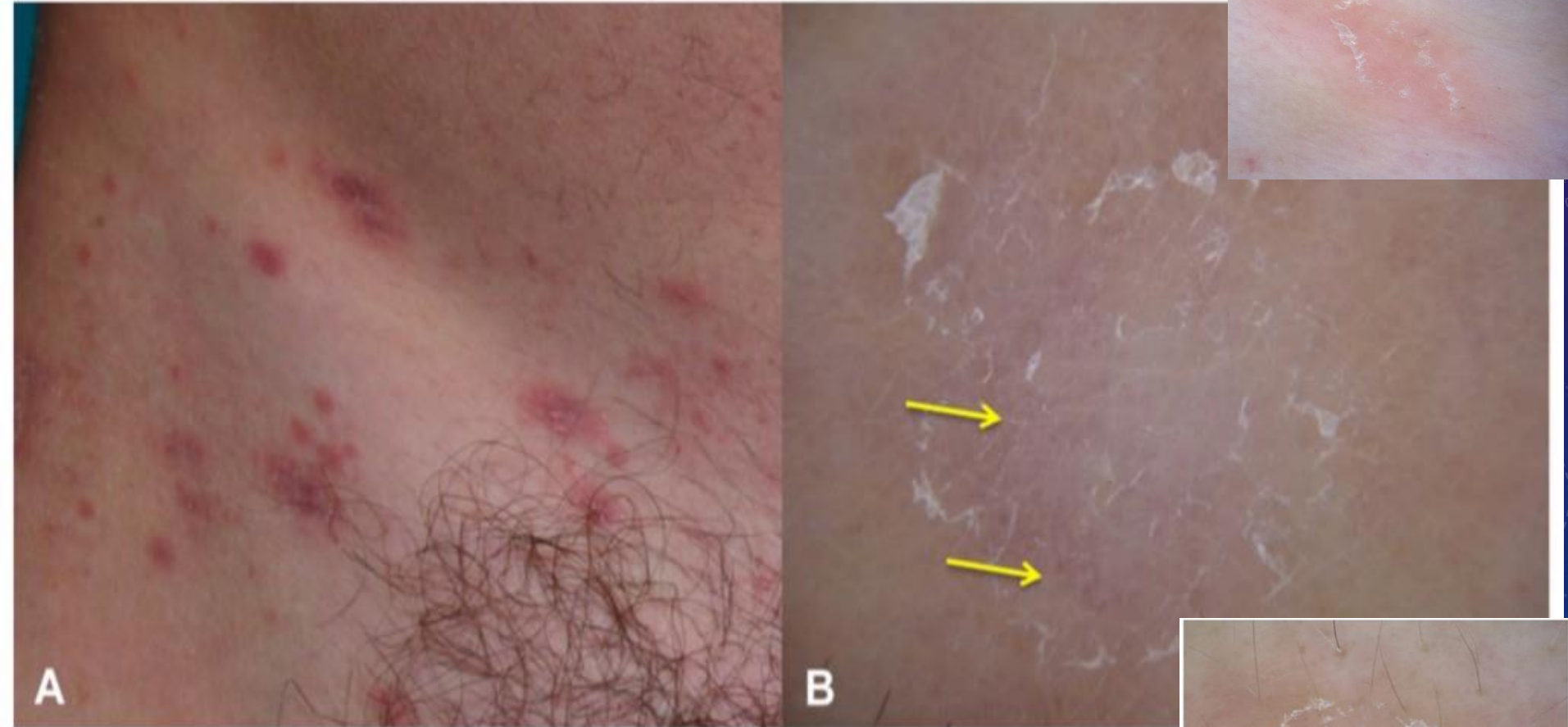


Table 1 Dermoscopic features observed in pityriasis lichenoides chronica and guttate psoriasis.

| Dermoscopic finding | Pityriasis lichenoides chronica (n = 8), n (%) | Guttate psoriasis (n = 9), n (%) |
|---------------------------------------|--|----------------------------------|
| Orange-yellowish structureless areas* | 7 (87.5) | 1 (11.1) |
| Hypopigmented areas | 1 (12.5) | 0 (0.0) |
| Dotted vessels | 5 (62.5) | 9 (100.0) |
| Focal distribution* | 5 (62.5) | 0 (0.0) |
| Diffuse distribution* | 0 (0.0) | 9 (100.0) |
| Nondotted vessels* | 7 (87.5) | 0 (0.0) |
| Linear irregular vessels* | 6 (75.0) | 0 (0.0) |
| Linear branching vessels | 4 (50.0) | 0 (0.0) |
| Milky-red areas/globules | 2 (25.0) | 0 (0.0) |

- Sarı-turuncu yapısız alanlar
- Fokal noktasal damarlar, lineer düzensiz, dallanan damarlar
- Guttat psoriasis ile ayırıcı tanı

Pityriasis rosea



A

B

- Periferik (yakacık/koloret) beyaz skuam
- Düzensiz dağılımda, fokal noktasal damarlar
- Sarı-turuncu yapısız alan

Liken planus

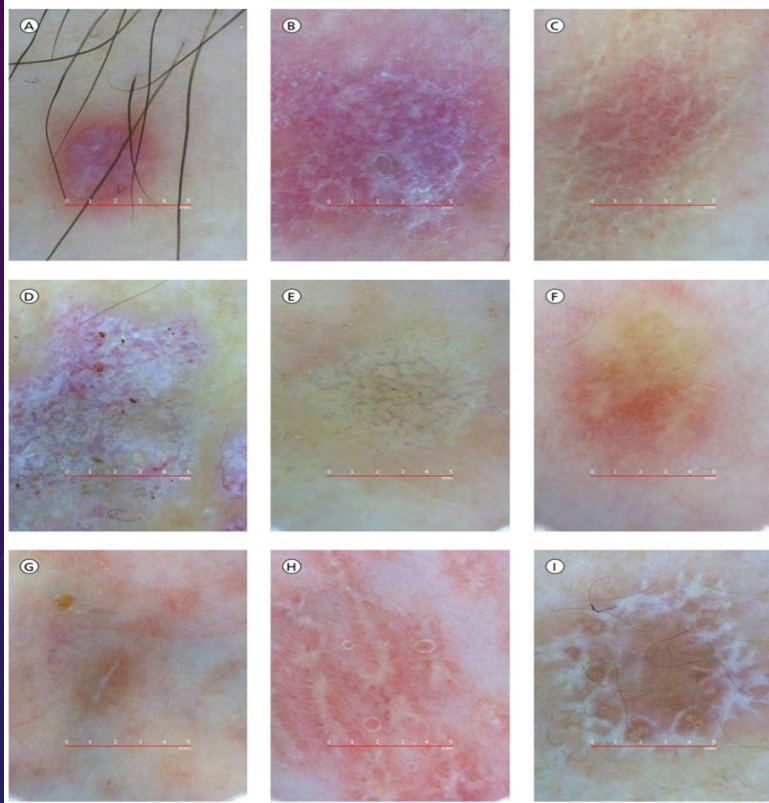
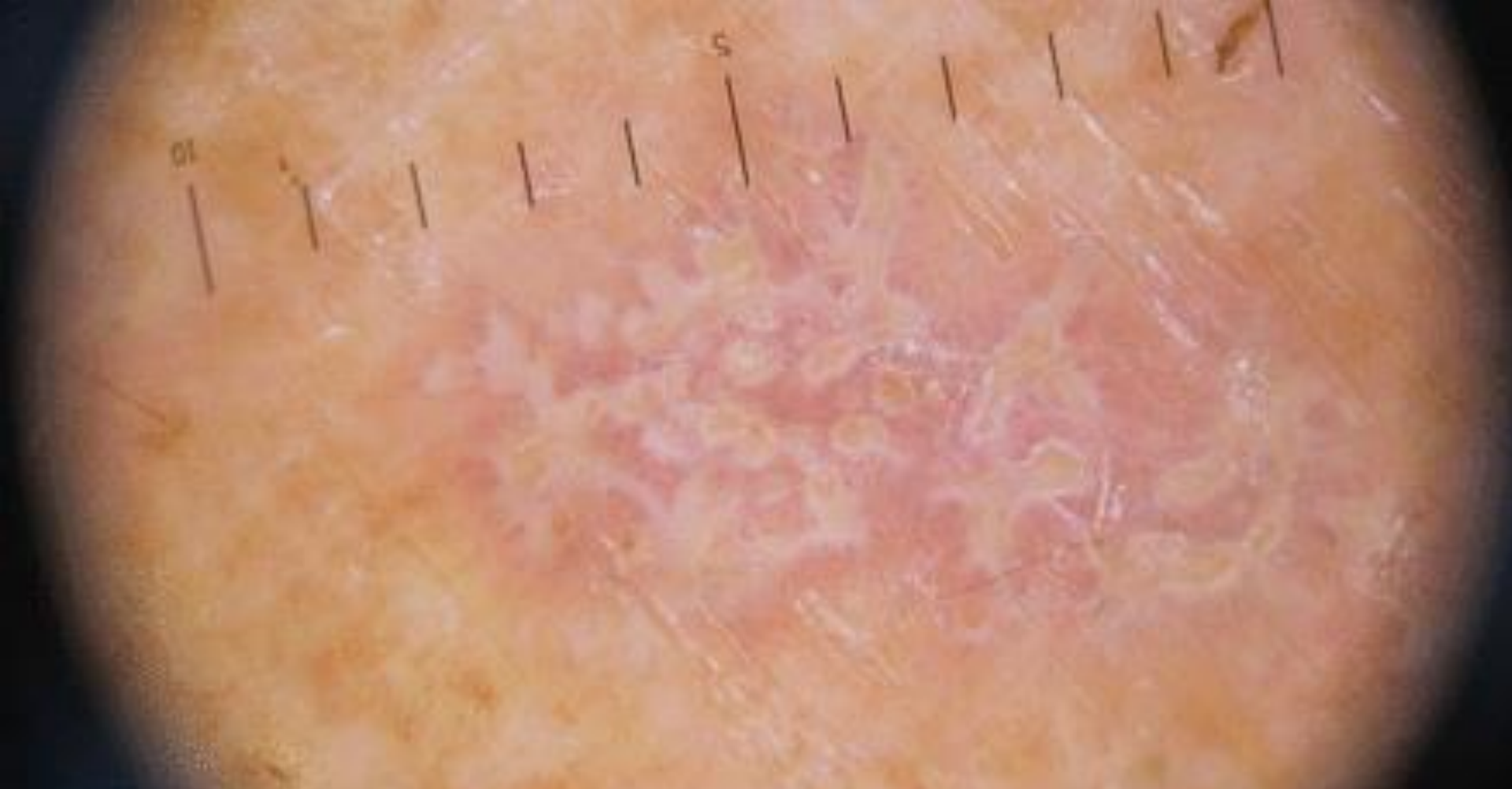


TABLE 1. Dermoscopic patterns in active or regressive LP and LP variants.

| | CIP 170 lesions N (%) | AGIP 30 lesions N (%) | LPp 15 lesions N (%) | LPPI 15 lesions N (%) | SLPP 1 lesion N (%) | 2LP 3 lesions N (%) | GAIP 1 lesion N (%) | AAIP 10 lesions N(%) | Ac LP 10 lesions N(%) | RIP 50 lesions N (%) |
|------------------------|-----------------------------|-----------------------------|----------------------------|-----------------------------|---------------------------|---------------------------|---------------------------|----------------------------|-----------------------------|----------------------------|
| WS | 152(89,4) | 18(60) | 6(40) | - | - | - | 1(100) | 7(70) | - | - |
| Morphology | | | | | | | | | | |
| Reticular | 110(64,7) | 10(33,3) | 1(6,6) | | | | | | | |
| Circular | 2(1,1) | 4(13,3) | 1(6,6) | | | | 1(100) | 7(70) | | |
| Linear | 13(7,6) | | 1(6,6) | | | | | | | |
| Globular | 13(8,8) | | 3(20) | | | | | | | |
| Radial streaming | 9(5,2) | | 1(6,6) | | | | | | | |
| Perpendicular | - | 4(13,3) | 5(33,3) | | | | | | | |
| Wick like | - | 4(13,3) | 9(60) | | | | | | | |
| Combined | 3(1,7) | | - | | | | | | | |
| Color | | | | | | | | | | |
| White | 112(65,8) | 10(33,3) | | | | | 1(100) | 7(70) | | |
| Yellow | 13(7,6) | 4(13,3) | | | | | | | | |
| Blue-white | 27(15,8) | 4(13,3) | | | | | | | | |
| WS (-) | 18(10,5) | 10(33,3) | | 15(100) | 1(100) | 3(100) | - | 3(50) | 10(100) | 50(100) |
| Invisible WS | - | 2(6,6) | | | | | - | | | |
| Pigment pattern | 20(11,7) | - | 15(86,6) | 15(100) | 1(100) | 3(100) | 1(100) | 10(100) | 10(100) | 30(60) |
| Dust/globules | | | | | | | | | | |
| -peripheral | 8(4,7) | | | | | | | | | 6(12) |
| -diffuse | | | | 5(33,3) | | 3(100) | | | | 6(12) |
| Peppering | | | | | | | | | | |
| -peripheral | | | | | | | | | | 3(6) |
| -diffuse | | | | 3(20) | 1(100) | | | | 10(100) | 3(6) |
| Perifollicular/annular | | | 8(53,3) | 8*(53,3) | 1*(100) | | | 2(20) | - | 2*(4) |
| Linear | | | | | | | | | | 2*(4) |
| Reticular | 2(1,1) | | | | | | | 3(20) | | 1*(2) |
| Circular | | | | | | | | | | 1(2) |
| Cobblestone | | | | | 3*(20) | | | | | 2*(4) |
| Homogen cloud like | | | | | | | | | | |
| -peripheral | 10(5,8) | | | | | | | | | 1(2) |
| -diffuse | | | 5(33,3) | | | | 1(100) | 8(80) | | 1(2) |
| Pigment pattern (-) | 150(88,2) | 30(100) | 2(13,5) | - | - | - | - | - | - | 20(40) |
| Vascular pattern | 46(27) | 24(80) | 3(20) | - | - | - | 1(100) | 3(50) | - | - |
| Red dots | | | | | | | | | | |
| -perifollicular | | 6(20) | | | | | | | | |
| -peripheral | 4(2,3) | 5(16,6) | | | | | 1(100) | | | |
| -diffuse | 15(8,8) | 9(30) | 3(30) | | | | | | | |
| Red globules | 8(4,7) | 4(13,3) | | | | | | | | |
| Radial linear | 19(11,1) | | | | | | | | | |
| Peripheral homogen | | | | | | | | 3(50) | | |
| Vascular pattern (-) | 124(72,9) | 6(20) | 12(80) | 15(100) | 1(100) | 3(100) | - | 7(70) | 10(100) | 50(100) |

- Pembe zemin
- Damarsal yapılar: noktasal, globüler, kısa lineer, kıvrıntılı damarlar
- Spesifik ipucu: birbirini dikey eksenlerde kesen beyaz çizgiler (wickham stria)
- İyileşen lezyonlarda diffüz kahverengi pigmentasyon, kahverengi-gri noktalar
- Dermatoskopik bulgular hastalığın aktif/regresif fazına göre, yerleşimine göre değişmekte

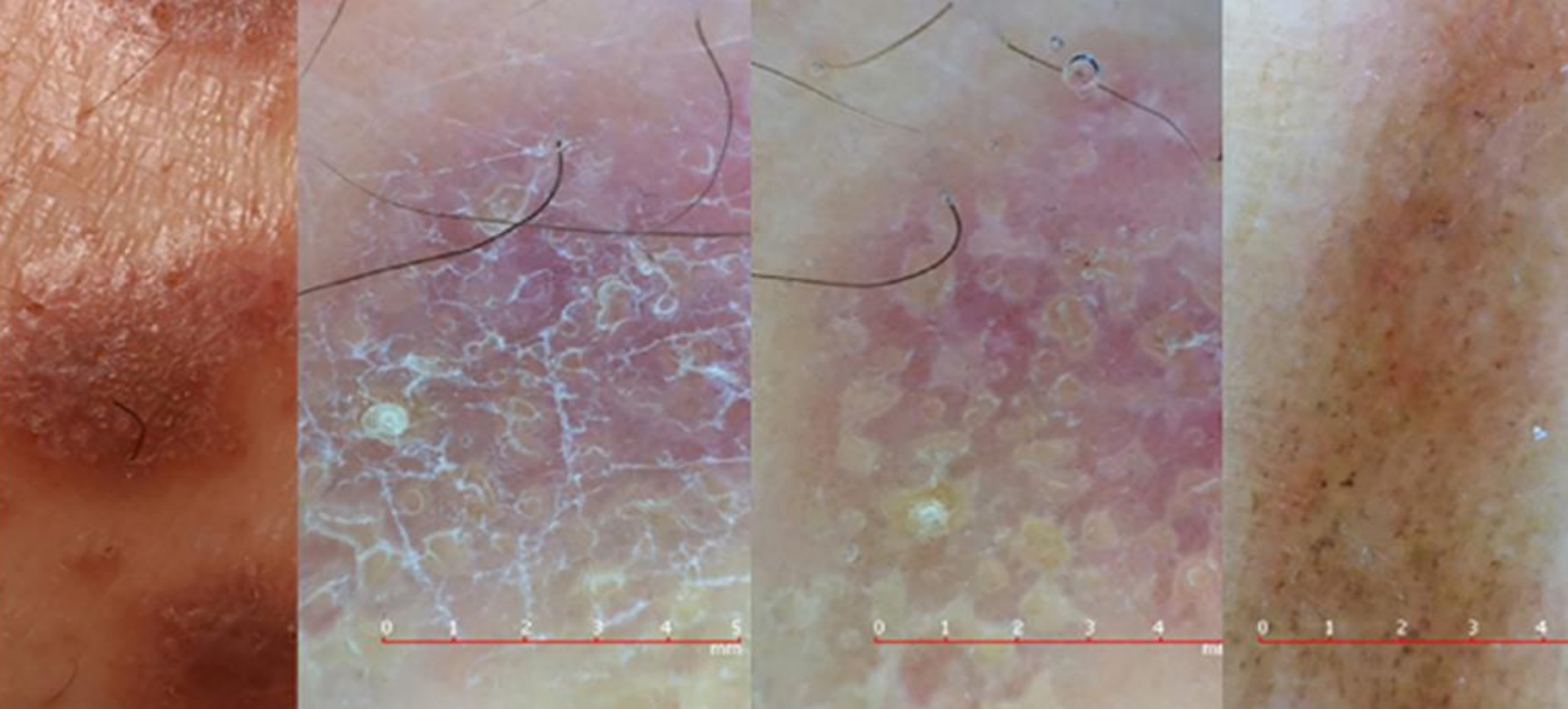
Beyaz çizgiler (Wickham stria)



Histopatolojik olarak hipergranülozu yansıtır

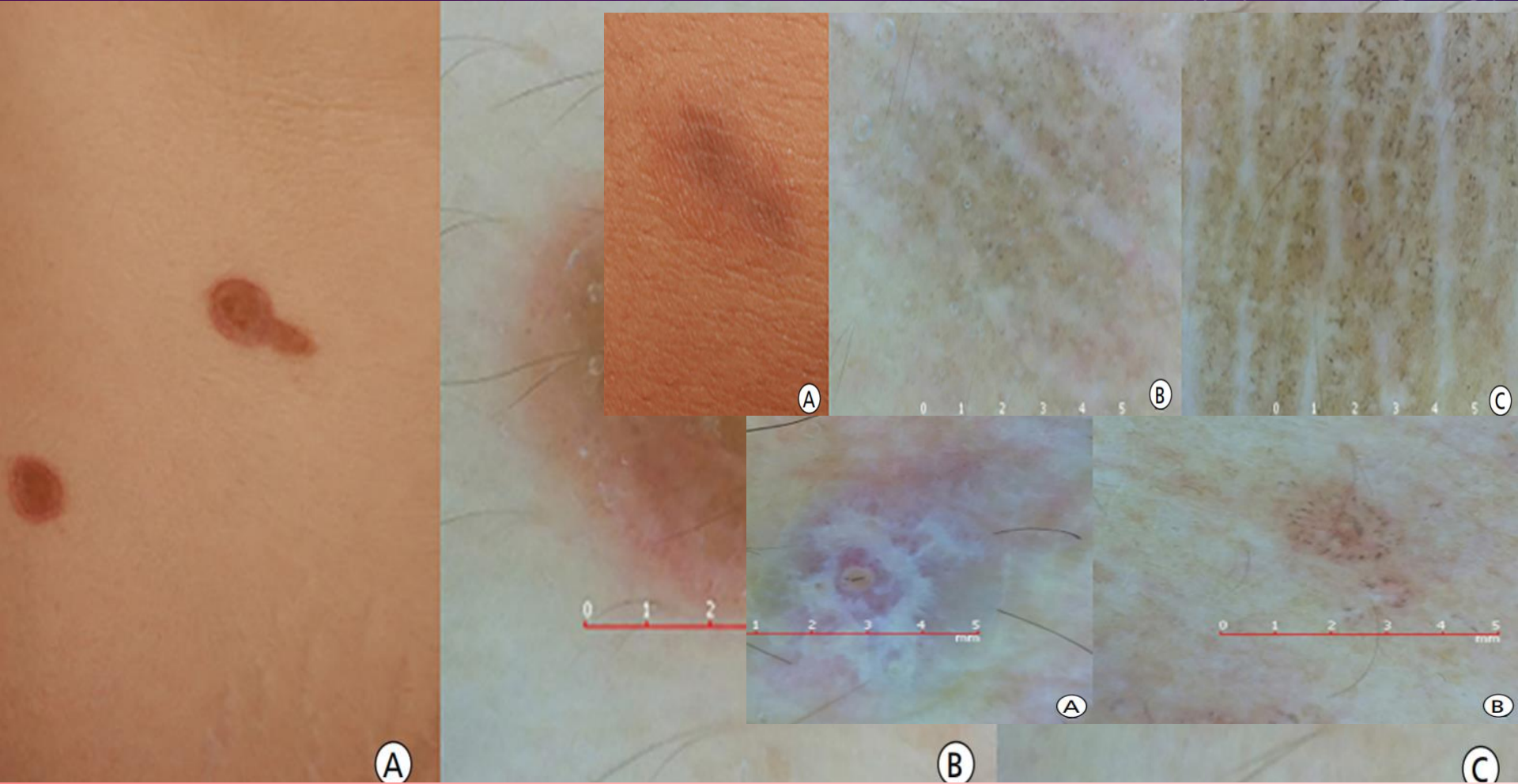
Beyaz, sarı veya mavi renkte olabilir

Kahverengi noktalar



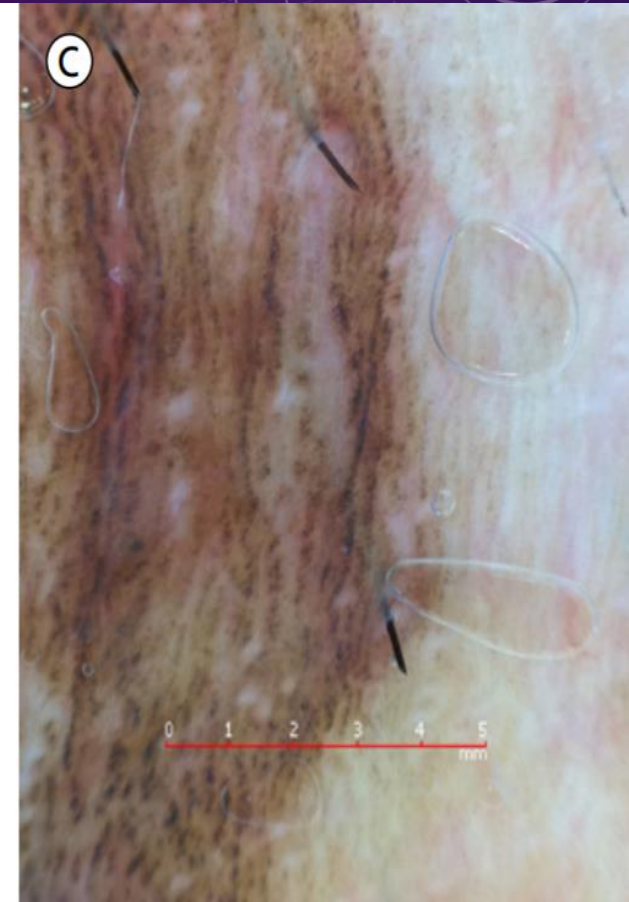
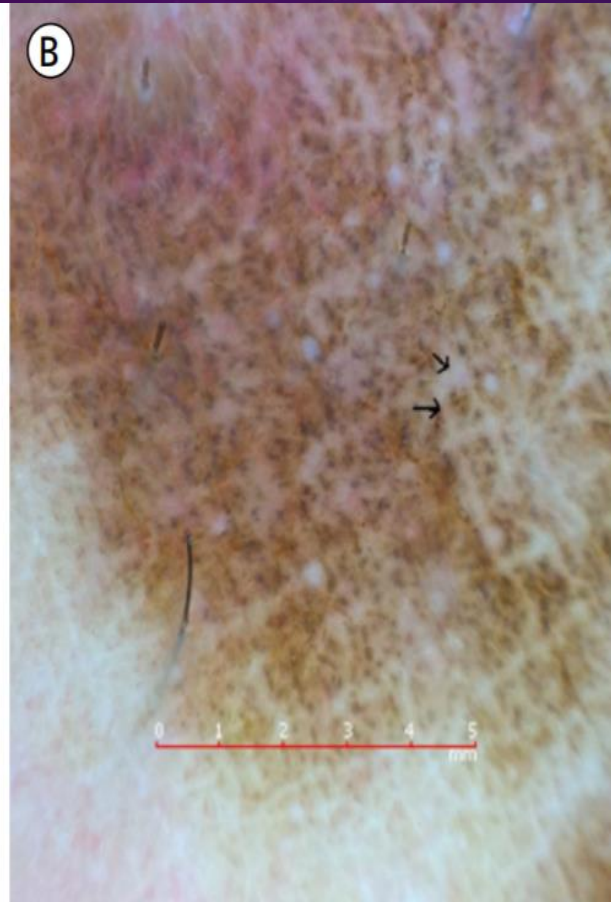
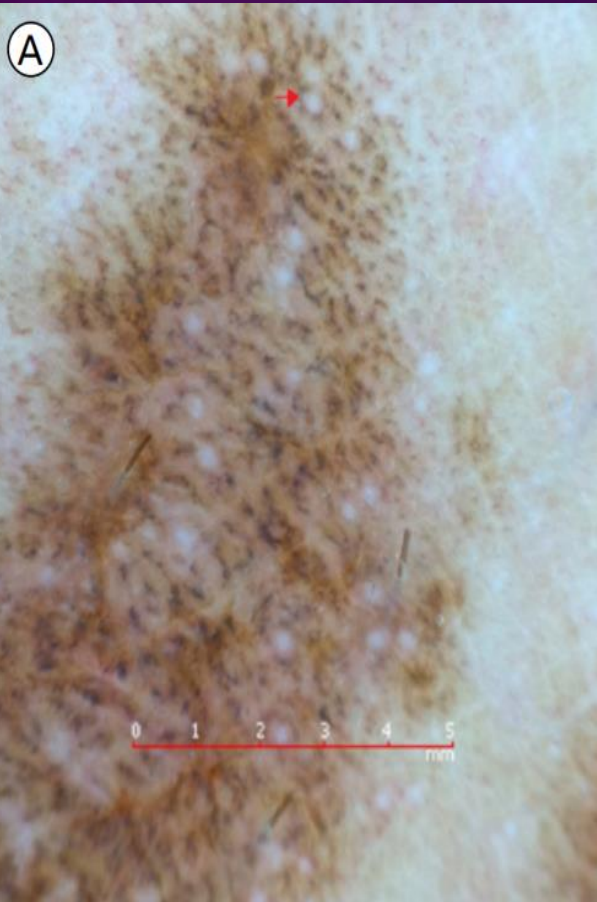
- Hastanın deri tipi
- Tedavi durumu
- Liken planus yerleşim yeri

Liken planus



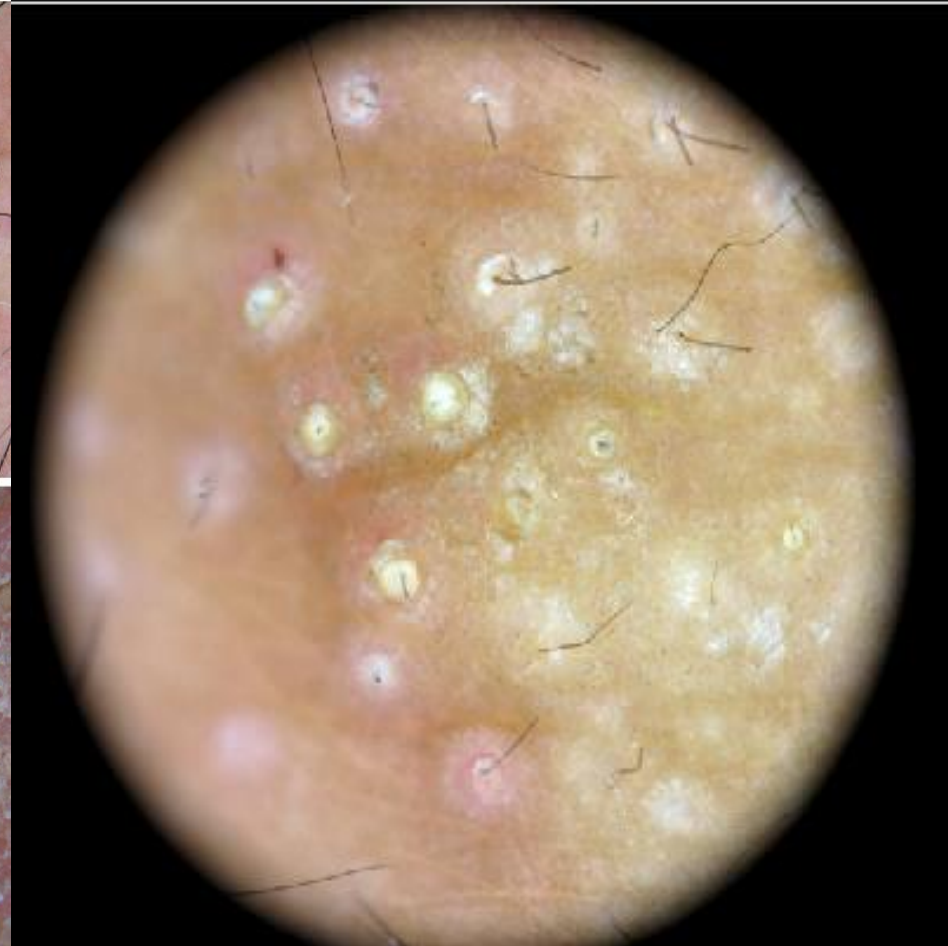
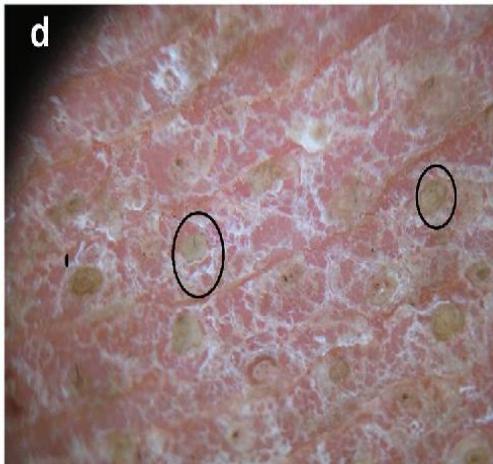
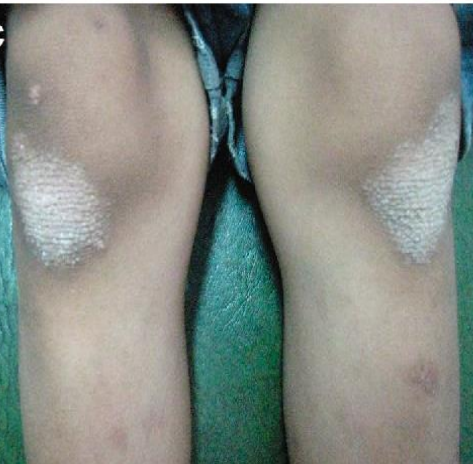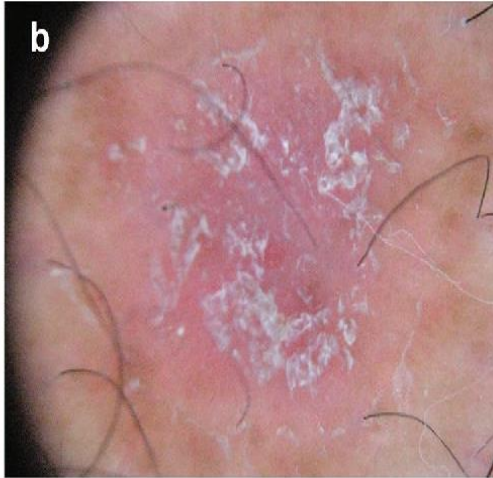
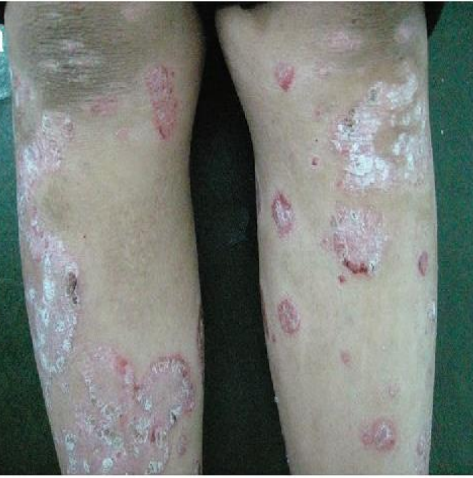İyileşen lezyonlarda difüz kahverengi pigmentasyon

Liken planus



Liken planus inversusta perifoliküler, retiküler ve lineer kahverengi noktalar

Pityriasis Rubra Pilaris

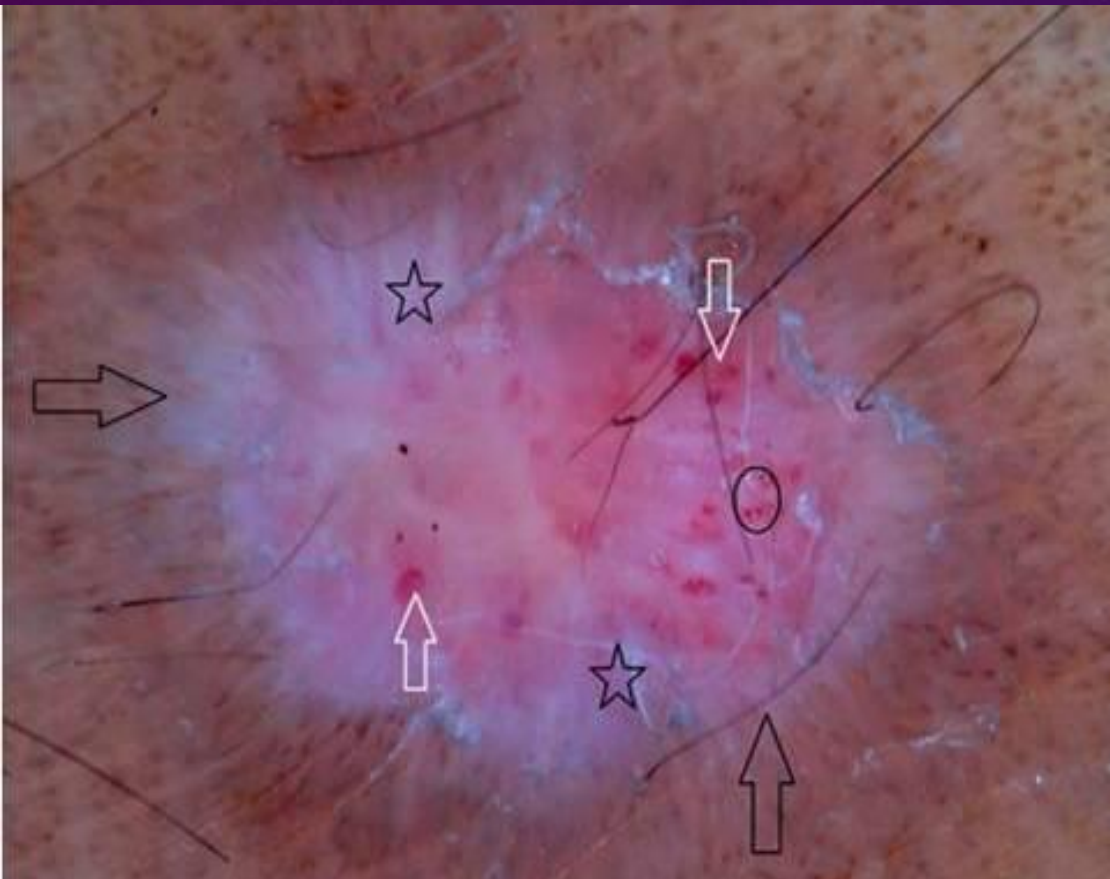


- Beyaz keratotik foliküler tıkaçlar
- Noktasal/Lineer damarlar

- Perifoliküler sarı/turuncu renkte halo

Pap lokeratotik Deri Hastalıklarında Dermatoskopi

Prurigo nodularis



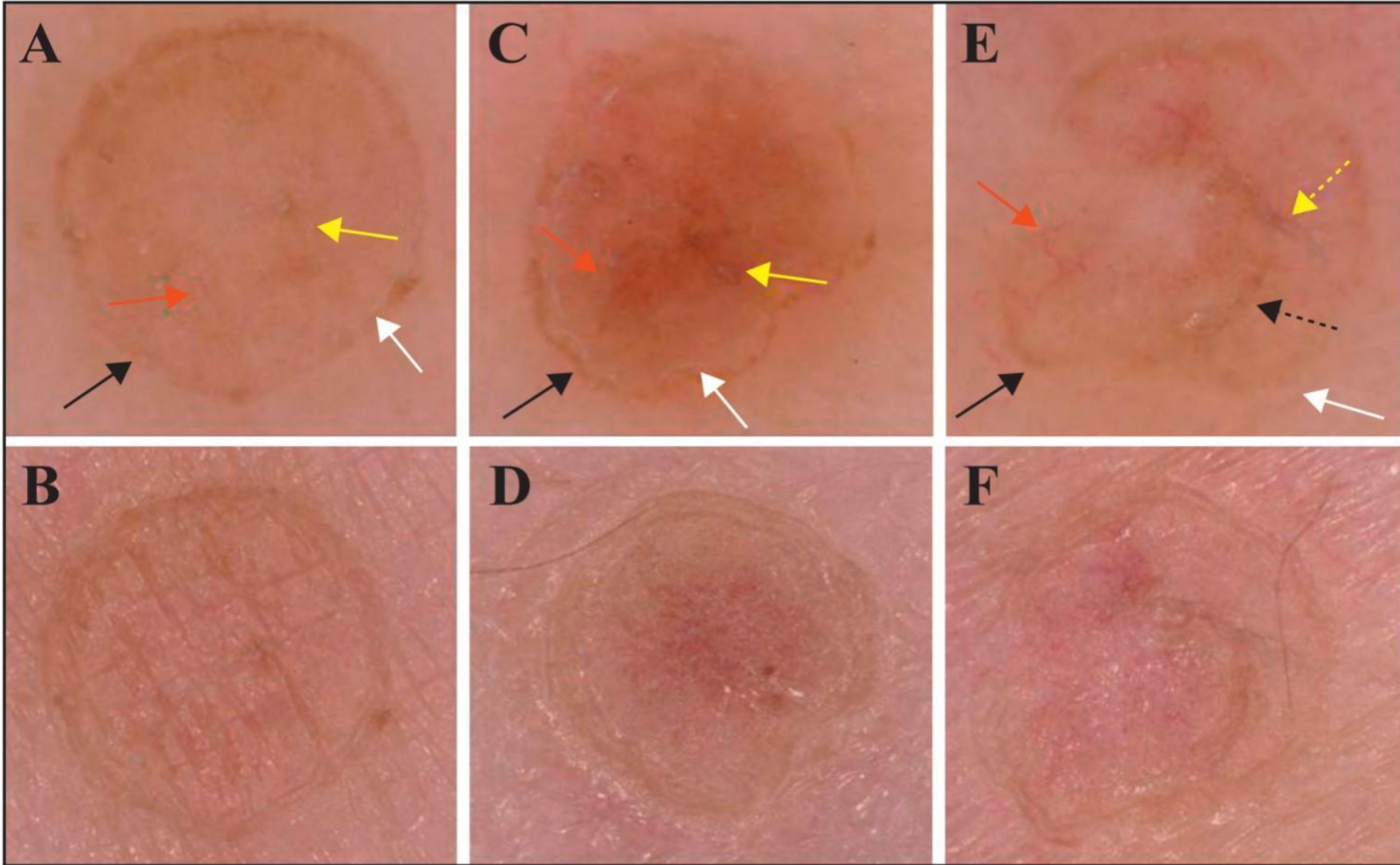
- Beyaz, yıldız saçılmış manzarası
- Kırmızı-kahverengi krutlar
- Noktasal, glomerüler damarlar
- Erozyon
- Hiperkeratotik skuam

Table 1. Dermoscopic features observed in prurigo nodularis with relative frequencies in hyperkeratotic and excoriated lesions

| Type of lesion | White starburst pattern, [†] <i>n</i> (%) | Hyperkeratosis/scales, [‡] <i>n</i> (%) | Crusts (single or multiple), [§] <i>n</i> (%) | Erosions (single or multiple), <i>n</i> (%) | Follicular plugging, <i>n</i> (%) | Hemorrhagic spots, <i>n</i> (%) | Dotted/glomerular vessels, <i>n</i> (%) |
|----------------|--|--|--|---|-----------------------------------|---------------------------------|---|
| Hyperkeratotic | 14 (100.0) | 14 (100.0) | 12 (85.7) | 9 (64.3) | 4 (28.6) | 5 (35.7) | 7 (50.0) |
| Excoriated | 14 (100.0) | 12 (85.7) | 10 (71.4) | 10 (71.4) | 0 (0.0) | 5 (35.7) | 3 (21.4) |

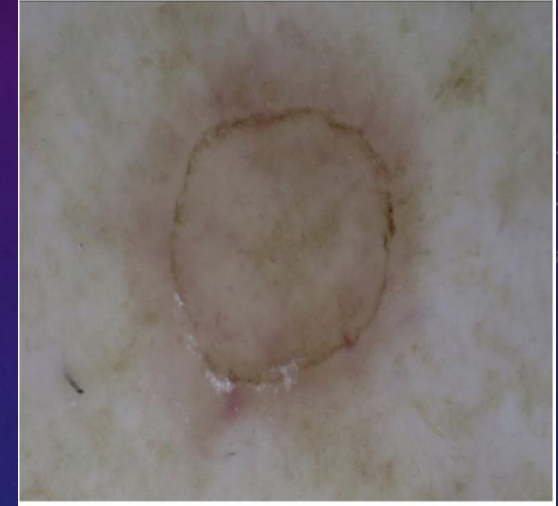
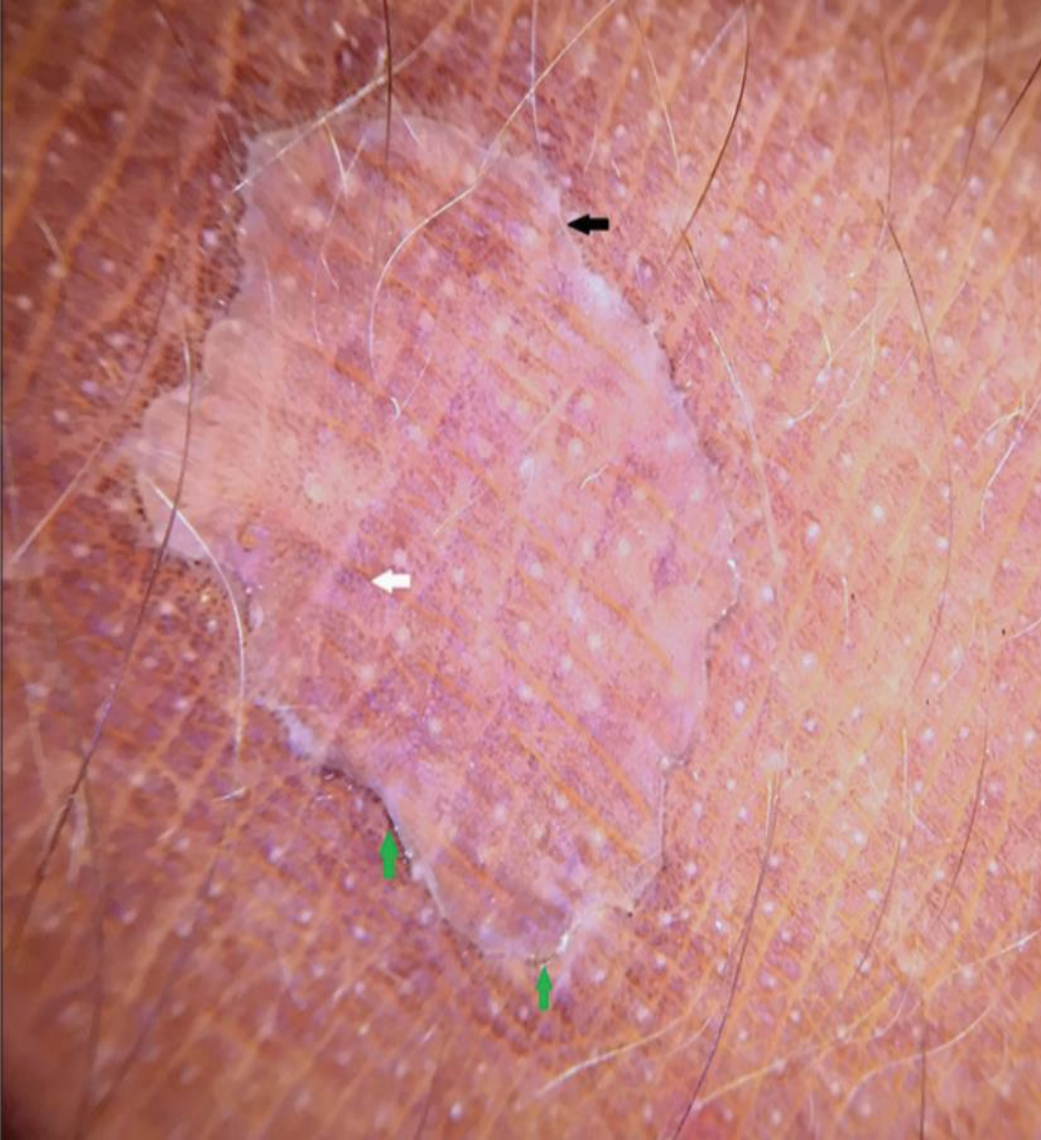
[†]The "white starburst pattern" consists of radially arranged whitish lines or peripheral whitish halo with some centrifugal coarse projections on a brownish and/or reddish background. [‡]In excoriated lesions the hyperkeratosis and/or the scales surrounded central crusts/erosions. [§]Brown-reddish and/or brown-yellowish crusts.

Porokeratoz



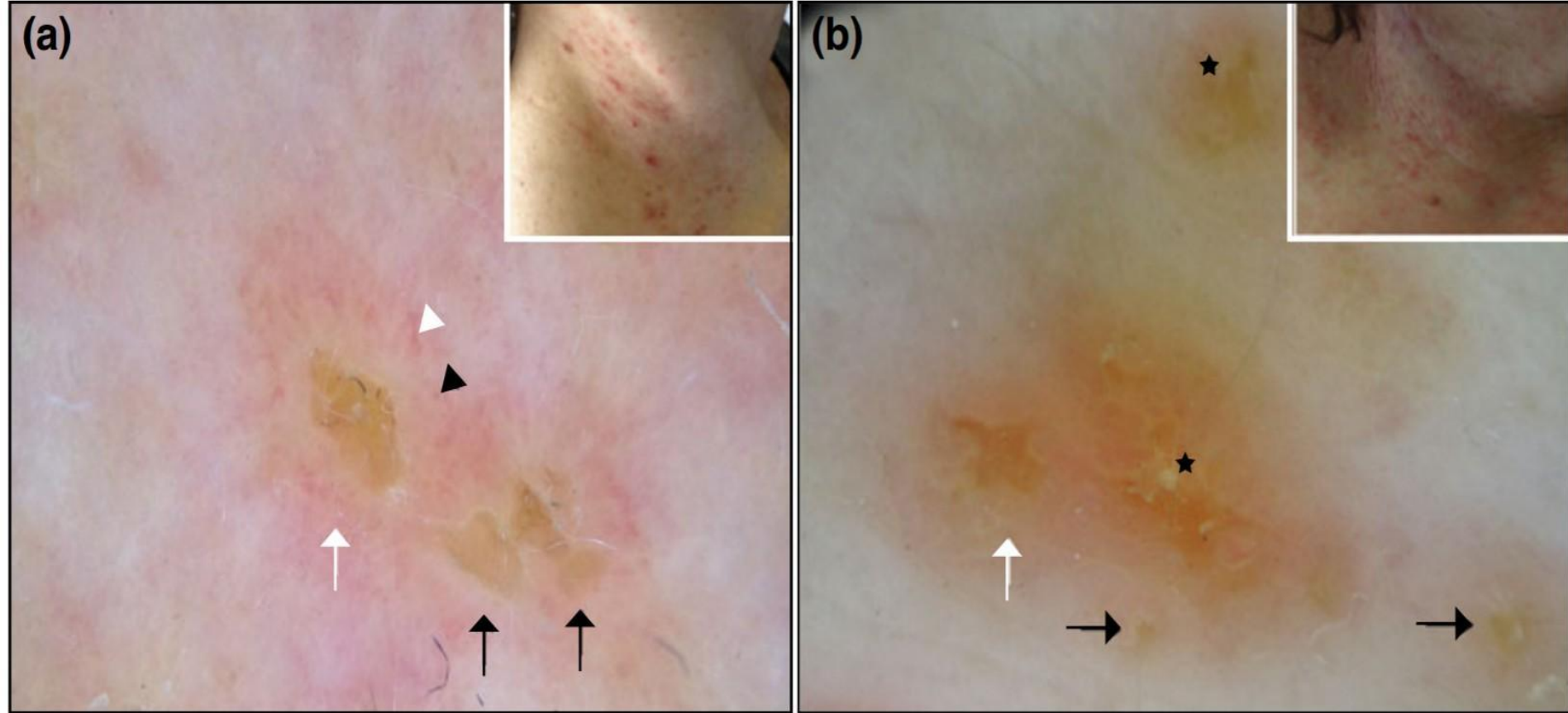
Keskin sınırlı, periferel beyaz-sarı anüler yapı (kornoid lamella)

Porokeratozlar



- Ortada kahverengi pigmentasyon
- Noktasal/lineer damarlar
- Dissemine süperfisyel aktinik porokeratozlarda periferel hat hiperpigmente olabilir

Darier Hastalığı



- Pembe zemin
- Sarı/kahverengi psödokomedon yapıları
- Noktasal ve lineer damarlar

Darier hastalığı

Table 1 Summary of dermoscopic features of the target lesions of the patients with histopathologically proven classic Darier's disease included in the present study

| Patient (gender, age and localization of the target lesion) | Central yellowish or brownish area with a whitish halo (shape) | Pinkish homogeneous structureless background | Whitish scales surrounding the yellowish or brownish area | Vessels (morphology) |
|---|--|--|---|----------------------|
| 1 (F 19 neck) | + (star-like) | + | - | + (dotted) |
| 2 (F 21 trunk) | + (star-like) | + | - | + (dotted) |
| 3 (F 24 trunk) | + (polygonal) | + | + | + (dotted) |
| 4 (F 30 shoulder) | + (star-like) | + | - | - |
| 5 (M 30 trunk) | + (star-like) | + | - | - |
| 6 (F 33 trunk) | + (star-like) | + | + | + (dotted, linear) |
| 7 (F 34 neck) | + (polygonal) | + | - | + (dotted, linear) |
| 8 (M 36 trunk) | + (star-like) | + | - | - |
| 9 (F 45 trunk) | + (star-like) | + | + | + (linear) |
| 10 (M 51 trunk) | + (polygonal) | + | - | + (linear) |
| 11 (F 56 neck) | + (star-like) | + | - | - |
| Total | 11 (100.0%) | 11 (100.0%) | 3 (27.3%) | 7 (63.6%) |

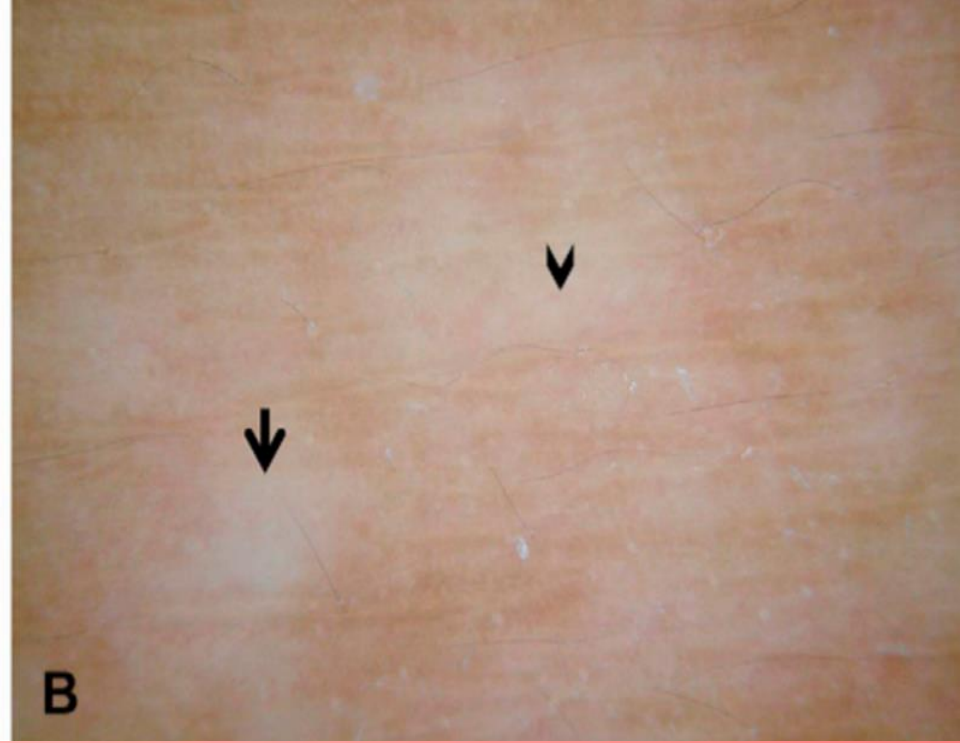
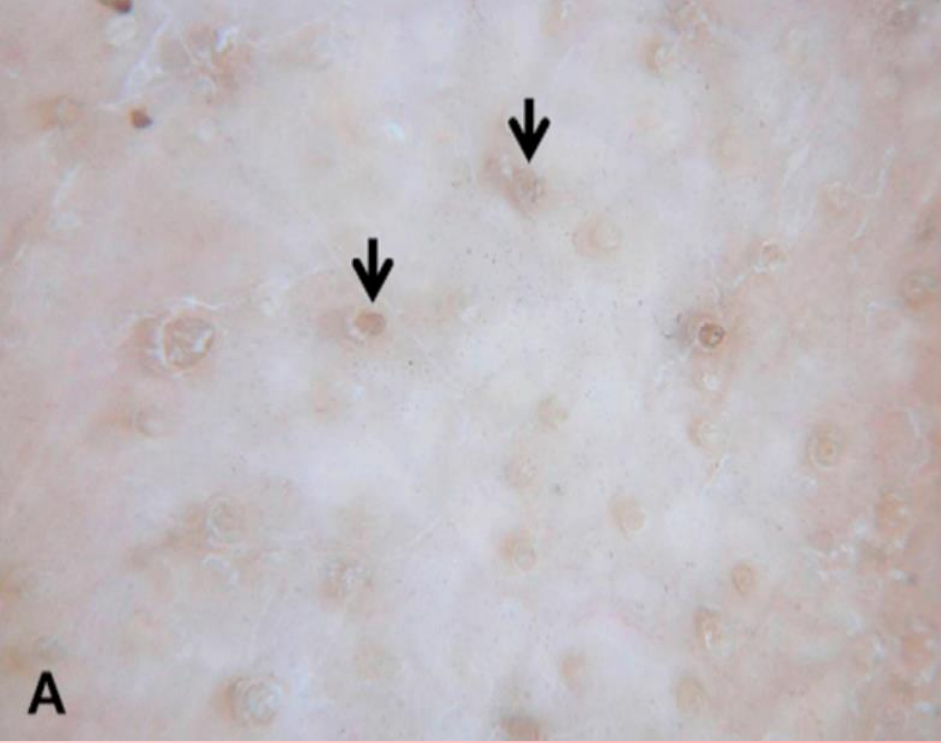
■ Beyaz halo ile çevrili, santral, yıldız benzeri veya poligonal yapıda sarı- kahverengi alanlar

■ Pembe, homojen zemin

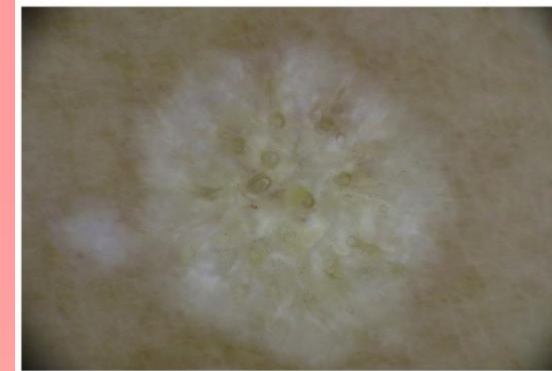■ Noktasal/lineer damarlar

Skleroatrofik İnflamatuvar Deri Hastalıklarında Dermatoskopi

Liken skleroz



- Yama tarzında yapısız beyaz-sarı renkte alanlar
- Noktasal- lineer damarlar
- Erozyonlar, hemorajik alanlar, gri-mavi noktasal alanlar
- Sarı keratotik tıkaçlar (psödokomedon)
- Erken evre vitiligo ve morfea ile ayırıcı tanı



Dermatoskopik bulgular hastalık süresine göre değişebilir..

Table 3. Dermoscopic features observed in lichen sclerosis lesions, according to the clinical stage

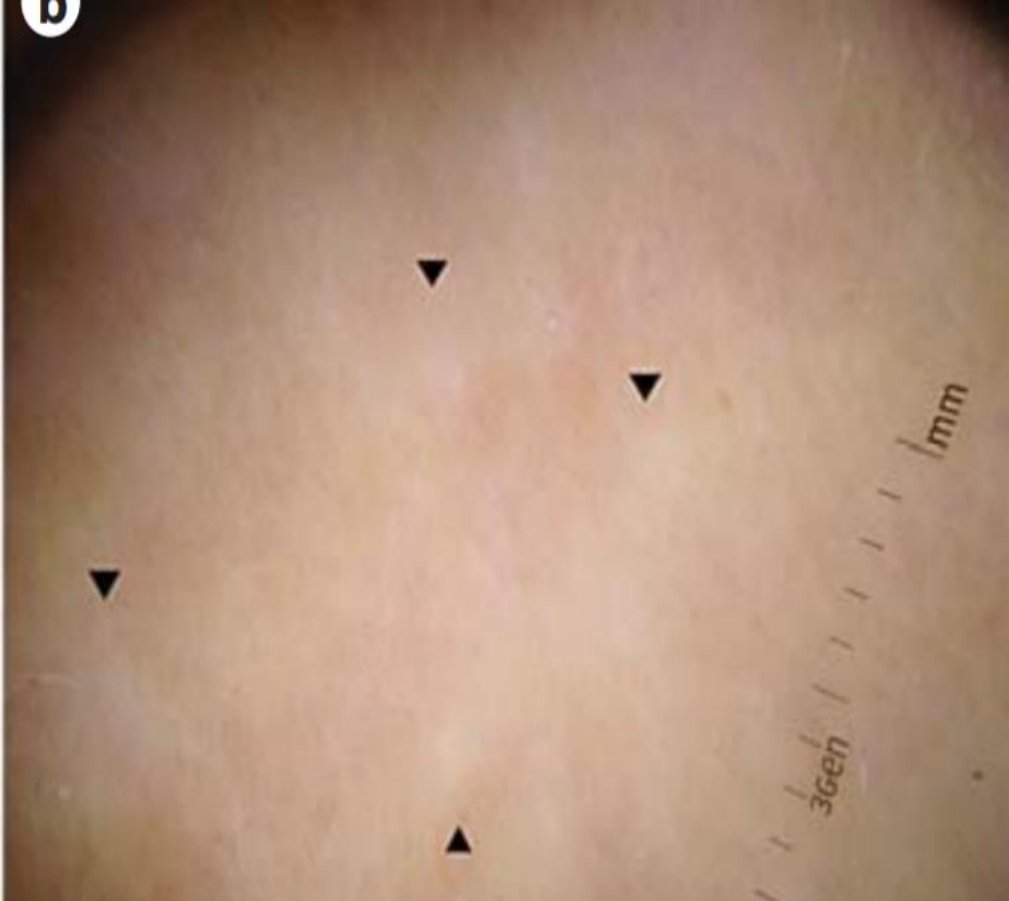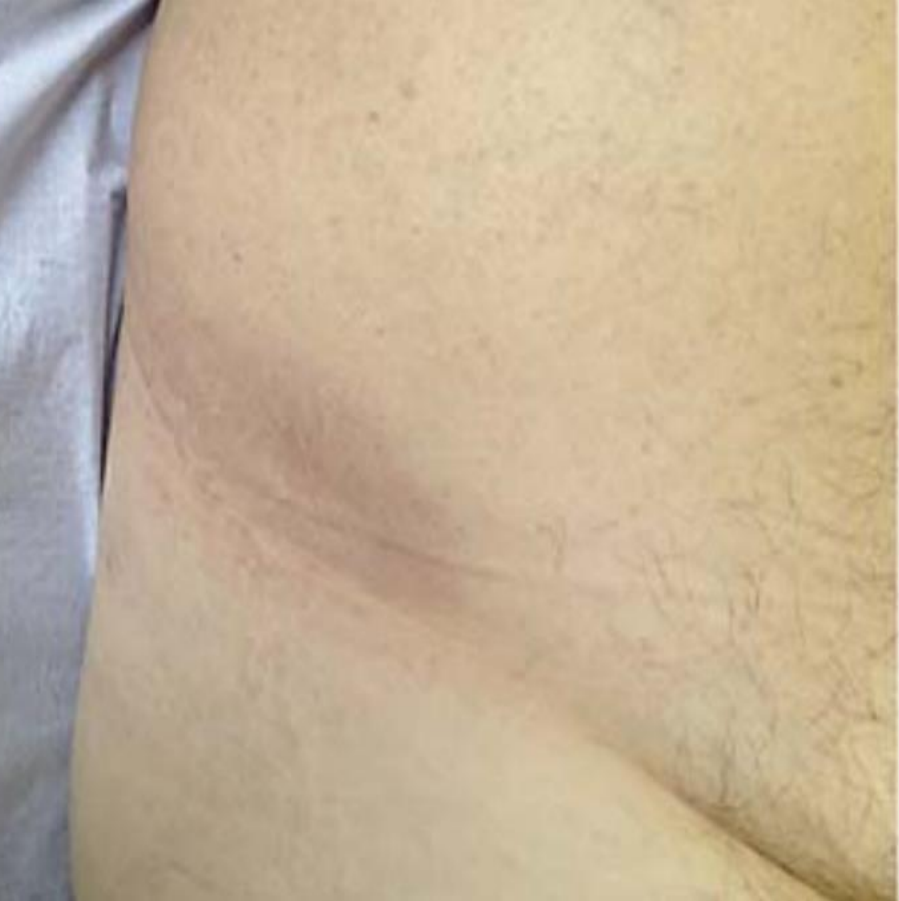| Dermoscopic findings | Inflammatory stage (n = 2), n (%) | Inflammatory-sclerotic stage (n = 16), n (%) | Sclerotic stage (n = 8), n (%) | Sclerotic-atrophic stage (n = 6), n (%) | Atrophic stage (n = 3), n (%) |
|--|---|--|--------------------------------------|---|-------------------------------------|
| "Inflammatory" findings | | | | | |
| Erythematous areas ^{a, b, c} | 2 (100.0) | 15 (93.8) | 1 (12.5) | 0 (0.0) | 0 (0.0) |
| Red focused vessels ^b | 1 (50.0) | 13 (81.3) | 2 (25.0) | 0 (0.0) | 0 (0.0) |
| Linear branching vessels | 1 (50.0) | 0 (0.0) | 0 (0.0) | 0 (0.0) | 0 (0.0) |
| Linear irregular vessels | 1 (50.0) | 6 (37.5) | 2 (25.0) | 0 (0.0) | 0 (0.0) |
| Dotted vessels | 0 (0.0) | 0 (0.0) | 0 (0.0) | 0 (0.0) | 0 (0.0) |
| Comma-like vessels | 0 (0.0) | 0 (0.0) | 0 (0.0) | 0 (0.0) | 0 (0.0) |
| Hairpin vessels | 0 (0.0) | 0 (0.0) | 0 (0.0) | 0 (0.0) | 0 (0.0) |
| "Sclerotic" findings | | | | | |
| White fibrotic beams/white clouds | 0 (0.0) | 0 (0.0) | 0 (0.0) | 0 (0.0) | 0 (0.0) |
| Crystalline structures | 1 (50.0) | 0 (0.0) | 0 (0.0) | 0 (0.0) | 0 (0.0) |
| Bright white/white-yellowish patches ^{c, d} | 2 (100.0) | 0 (0.0) | 0 (0.0) | 0 (0.0) | 0 (0.0) |
| "Atrophic" findings | | | | | |
| Unfocused large purple vessels ^b | 0 (0.0) | 0 (0.0) | 0 (0.0) | 0 (0.0) | 0 (0.0) |
| Yellowish structureless areas ^{c, d} | 0 (0.0) | 0 (0.0) | 0 (0.0) | 0 (0.0) | 0 (0.0) |
| Other findings | | | | | |
| Yellowish-white keratotic follicular plugs ^{c, d} | 1 (50.0) | 16 (100.0) | 8 (100.0) | 3 (50.0) | 0 (0.0) |
| Comedo-like follicular openings | 0 (0.0) | 1 (6.3) | 0 (0.0) | 0 (0.0) | 0 (0.0) |
| Pigmentary structures | 0 (0.0) | 0 (0.0) | 2 (25.0) | 2 (33.3) | 0 (0.0) |
| Structureless brownish areas | 0 (0.0) | 0 (0.0) | 0 (0.0) | 0 (0.0) | 0 (0.0) |
| Reticular brownish areas | 0 (0.0) | 0 (0.0) | 0 (0.0) | 0 (0.0) | 0 (0.0) |
| Brownish dots | 0 (0.0) | 0 (0.0) | 0 (0.0) | 0 (0.0) | 0 (0.0) |
| Scaling | 1 (50.0) | 0 (0.0) | 0 (0.0) | 0 (0.0) | 0 (0.0) |
| Rainbow effect | 0 (0.0) | 0 (0.0) | 0 (0.0) | 0 (0.0) | 0 (0.0) |
| Erosions | 0 (0.0) | 0 (0.0) | 0 (0.0) | 0 (0.0) | 0 (0.0) |
| Hemorrhagic spots | 1 (50.0) | 0 (0.0) | 0 (0.0) | 0 (0.0) | 0 (0.0) |

■ Erken inflammatuar evrede eritemli alanlar, noktasal veya lineer damarlar, sarı-beyaz keratotik tıkaçlar, kristaline yapılar, erozyon ve hemorajik krutlar daha sık

■ Skleroatrofik evrede homojen beyaz yapısız alanlar daha sık

^a $p < 0.01$, inflammatory-sclerotic versus sclerotic stage; ^b $p < 0.01$, inflammatory-sclerotic versus sclerotic-atrophic stage; ^c $p < 0.01$, inflammatory-sclerotic versus atrophic stage; ^d $p < 0.01$, sclerotic versus atrophic stage.

Morfea



- Beyaz fibrotik alanlar
- Lineer damarlar

Dermatoskopik bulgular hastalık süresine göre değişebilir..

Table 2. Dermoscopic features observed in morphea lesions, according to the clinical stage

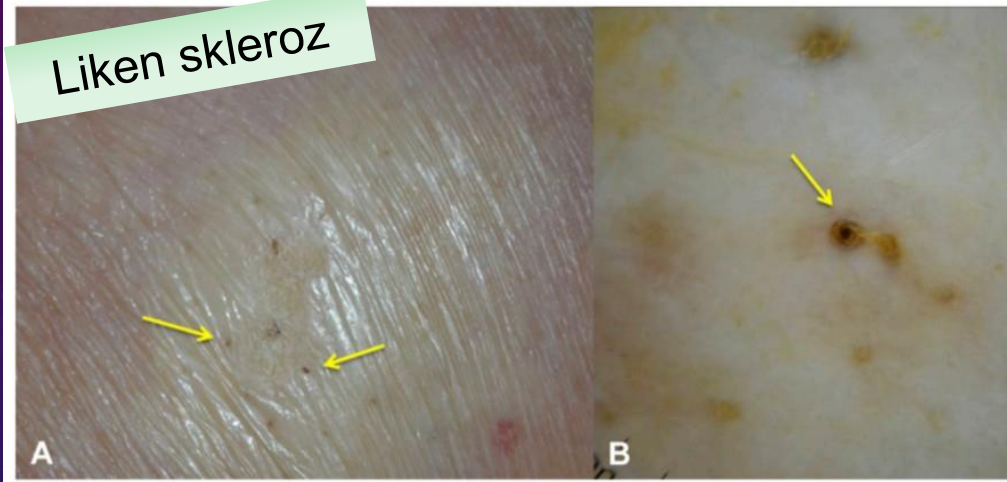
| Dermoscopic findings | Inflammatory stage (n = 9), n (%) | Inflammatory-sclerotic stage (n = 17), n (%) | Sclerotic stage (n = 16), n (%) | Atrophic stage (n = 9), n (%) |
|---|-----------------------------------|--|---------------------------------|-------------------------------|
| "Inflammatory" findings | | | | |
| Erythematous areas | 7 (77.8) | 11 (64.7) | 6 (37.5) | |
| Red focused vessels ^{a, b} | 8 (88.9) | 13 (76.5) | 8 (50.0) | |
| Linear branching vessels | 2 (22.2) | 1 (5.9) | 1 (6.3) | |
| Linear irregular vessels ^b | 7 (77.8) | 12 (70.6) | 6 (37.5) | |
| Dotted vessels | 1 (11.1) | 3 (17.6) | 4 (25.0) | |
| Comma-like vessels | 0 (0.0) | 0 (0.0) | 0 (0.0) | |
| Hairpin vessels | 0 (0.0) | 0 (0.0) | 0 (0.0) | |
| "Sclerotic" findings | | | | |
| White fibrotic beams/white clouds | 7 (77.8) | 13 (76.5) | 10 (62.5) | 4 (44.4) |
| Crystalline structures | 2 (22.2) | 3 (17.6) | 6 (37.5) | 0 (0.0) |
| Bright white/white-yellowish patches | 0 (0.0) | 0 (0.0) | 0 (0.0) | 0 (0.0) |
| "Atrophic" findings | | | | |
| Unfocused large purple vessels ^{a-c} | 0 (0.0) | 4 (23.5) | 3 (18.8) | 9 (100.0) |
| Yellowish structureless areas | 0 (0.0) | 1 (5.9) | 1 (6.3) | 3 (33.3) |
| Other findings | | | | |
| Yellowish-white keratotic follicular plugs | 0 (0.0) | 0 (0.0) | 0 (0.0) | 0 |
| Comedo-like follicular openings | 0 (0.0) | 0 (0.0) | 0 (0.0) | 0 |
| Pigmentary structures | 1 (11.1) | 7 (41.2) | 7 (43.8) | 7 |
| Structureless brownish areas | 0 (0.0) | 5 (29.4) | 4 (25.0) | 5 |
| Reticular brownish areas | 0 (0.0) | 2 (11.8) | 3 (18.8) | 2 |
| Brownish dots | 1 (11.1) | 0 (0.0) | 0 (0.0) | 0 |
| Scaling | 0 (0.0) | 2 (11.8) | 2 (12.5) | 0 |
| Rainbow effect | 0 (0.0) | 0 (0.0) | 1 (6.3) | 0 |
| Erosions | 0 (0.0) | 0 (0.0) | 0 (0.0) | 0 |
| Hemorrhagic spots | 0 (0.0) | 0 (0.0) | 0 (0.0) | 0 |

^a $p < 0.01$, inflammatory versus atrophic stage; ^b $p < 0.01$, inflammatory-sclerotic versus atrophic stage; ^c $p < 0.01$, sclerotic versus atrophic stage.

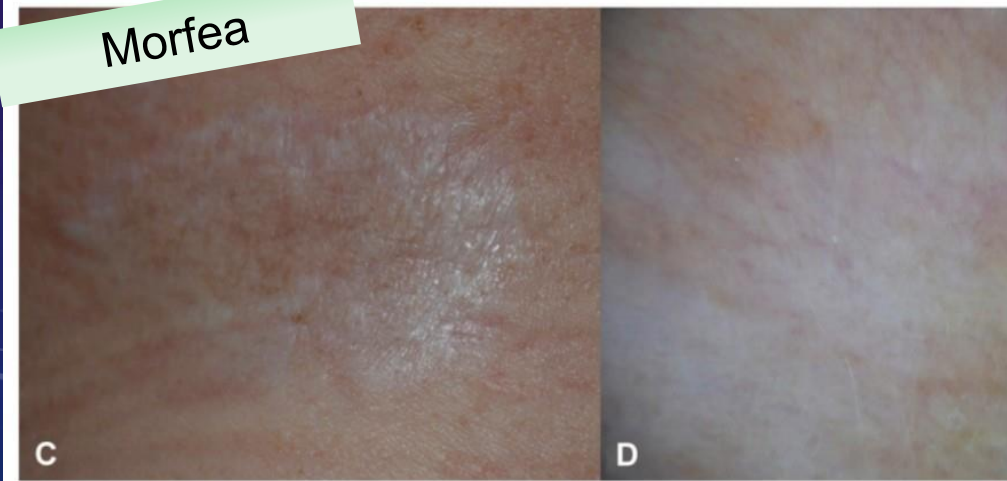
■ Erken evrede eritemli alanlar, lineer düzensiz damarlar, beyaz fibrotik alanlar

■ Atrofik evrede geniş morumsu damarlar ve pigment değişiklikleri, sarı yapısız alanlar daha sık

Liken skleroz



Morfea



- Beyaz fibrotik alanlar
- Komedon benzeri açıklıklar

Table 1. Dermoscopic features observed in morphea and cutaneous lichen sclerosis lesions

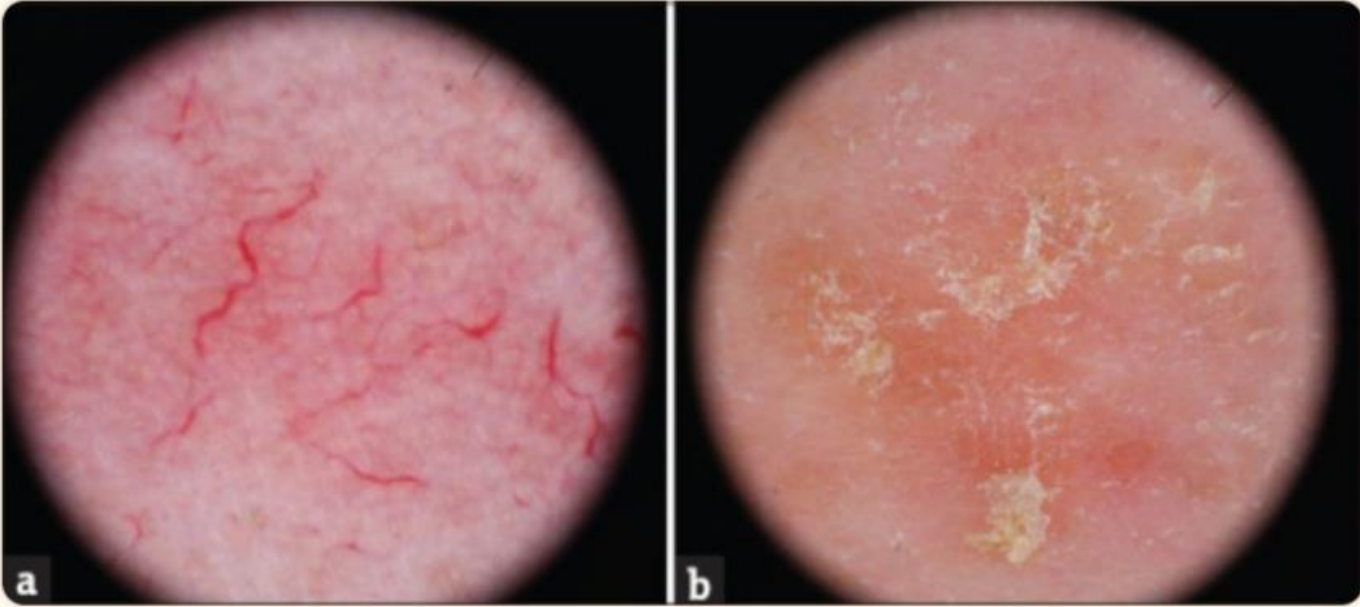
| Dermoscopic findings | Morphea (n = 51), n (%) | Cutaneous lichen sclerosis (n = 35), n (%) | p |
|---|-------------------------|--|---------|
| <i>"Inflammatory" findings</i> | | | |
| Erythematous areas | 25 (49.0) | 18 (51.4) | 0.8263 |
| Red focused vessels | 30 (58.8) | 16 (45.7) | 0.2312 |
| Linear branching vessels | 4 (7.8) | 1 (2.9) | 0.6442 |
| Linear irregular vessels | 26 (51.0) | 9 (25.7) | 0.0192 |
| Dotted vessels | 9 (17.6) | 10 (28.6) | 0.2303 |
| Comma-like vessels | 0 (0.0) | 0 (0.0) | 1 |
| Hairpin vessels | 0 (0.0) | 0 (0.0) | 1 |
| <i>"Sclerotic" findings</i> | | | |
| White fibrotic beams/white clouds* | 34 (66.7) | 0 (0.0) | <0.0001 |
| Crystalline structures | 11 (21.6) | 14 (40.0) | 0.0644 |
| Bright white/white-yellowish patches* | 0 (0.0) | 31 (88.6) | <0.0001 |
| <i>"Atrophic" findings</i> | | | |
| Unfocused large purple vessels | 16 (31.4) | 4 (11.4) | 0.0389 |
| Yellowish structureless areas | 5 (9.8) | 5 (14.3) | 0.5242 |
| <i>Other findings</i> | | | |
| Yellowish-white keratotic follicular plugs* | 0 (0.0) | 28 (80.0) | <0.0001 |
| Comedo-like follicular openings | 0 (0.0) | 1 (2.9) | 0.4070 |
| Pigmentary structures* | 22 (43.1) | 4 (11.4) | 0.0018 |
| Structureless brownish areas* | 14 (27.5) | 0 (0.0) | 0.0005 |
| Reticular brownish areas | 7 (13.7) | 2 (5.7) | 0.2998 |
| Brownish dots | 1 (2.0) | 2 (5.7) | 0.5640 |
| Scaling* | 4 (7.8) | 15 (42.9) | 0.0002 |
| Rainbow effect | 1 (2.0) | 1 (2.9) | 1 |
| Erosions | 0 (0.0) | 1 (2.9) | 0.4070 |
| Hemorrhagic spots* | 0 (0.0) | 14 (40.0) | <0.0001 |

* p < 0.01 between morphea and cutaneous lichen sclerosis lesions.

- Beyaz fibrotik alanlar
- Lineer damarlar

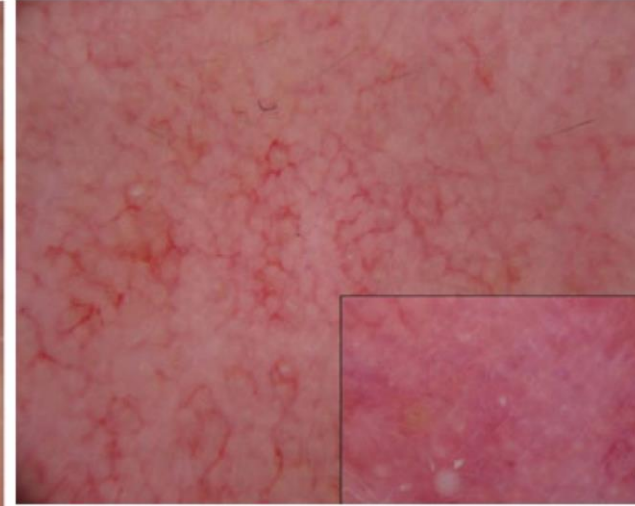
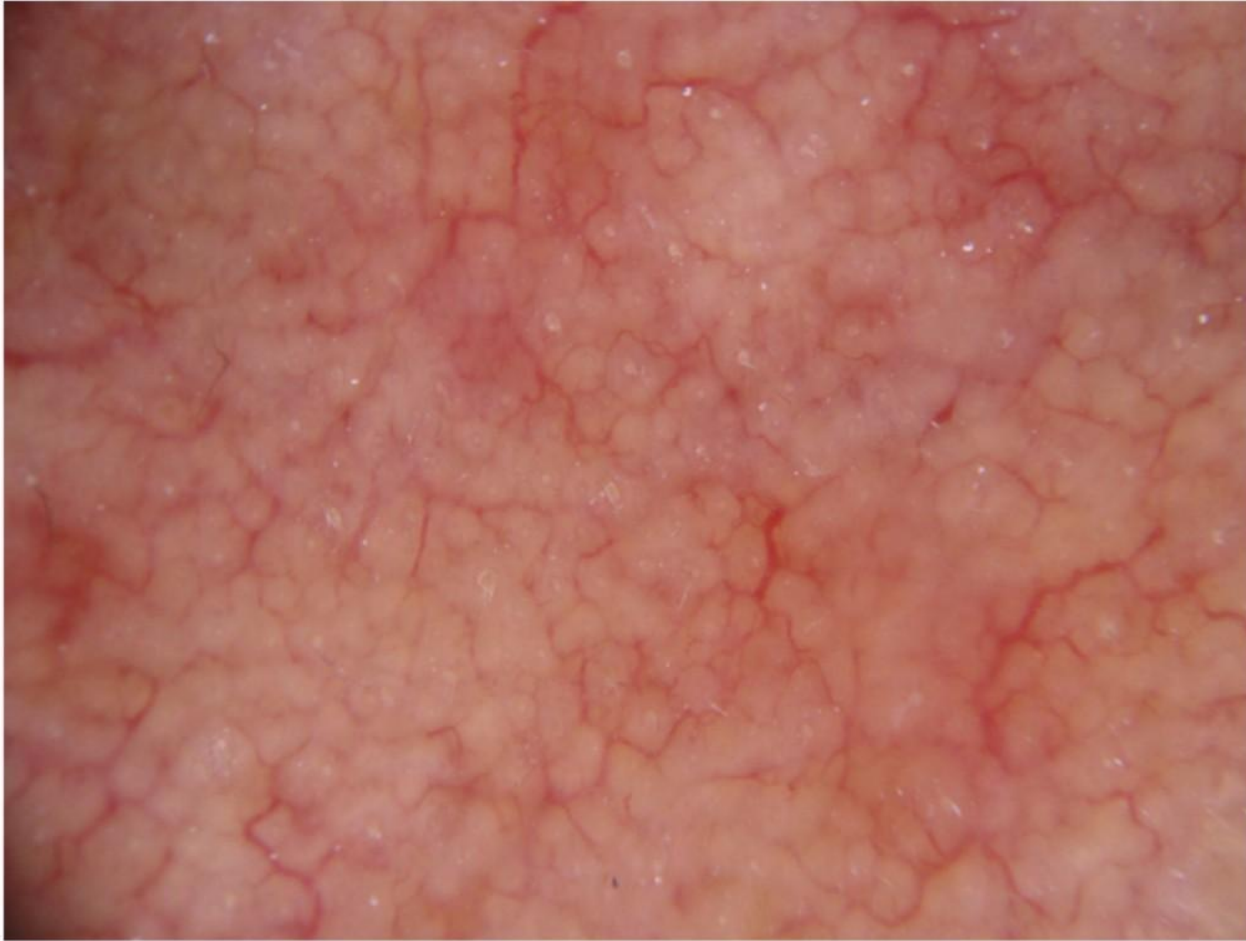Yüz Yerleşimli İnflamatuvar Deri Hastalıklarında Dermatoskopi

Seboreik dermatit



- Klasik dermatitlerdeki ile benzer dermatoskopik bulgular
- Yamasal dağılımda noktasal damarlar
- İnce sarı-beyaz skuamlar, seröz krutlar

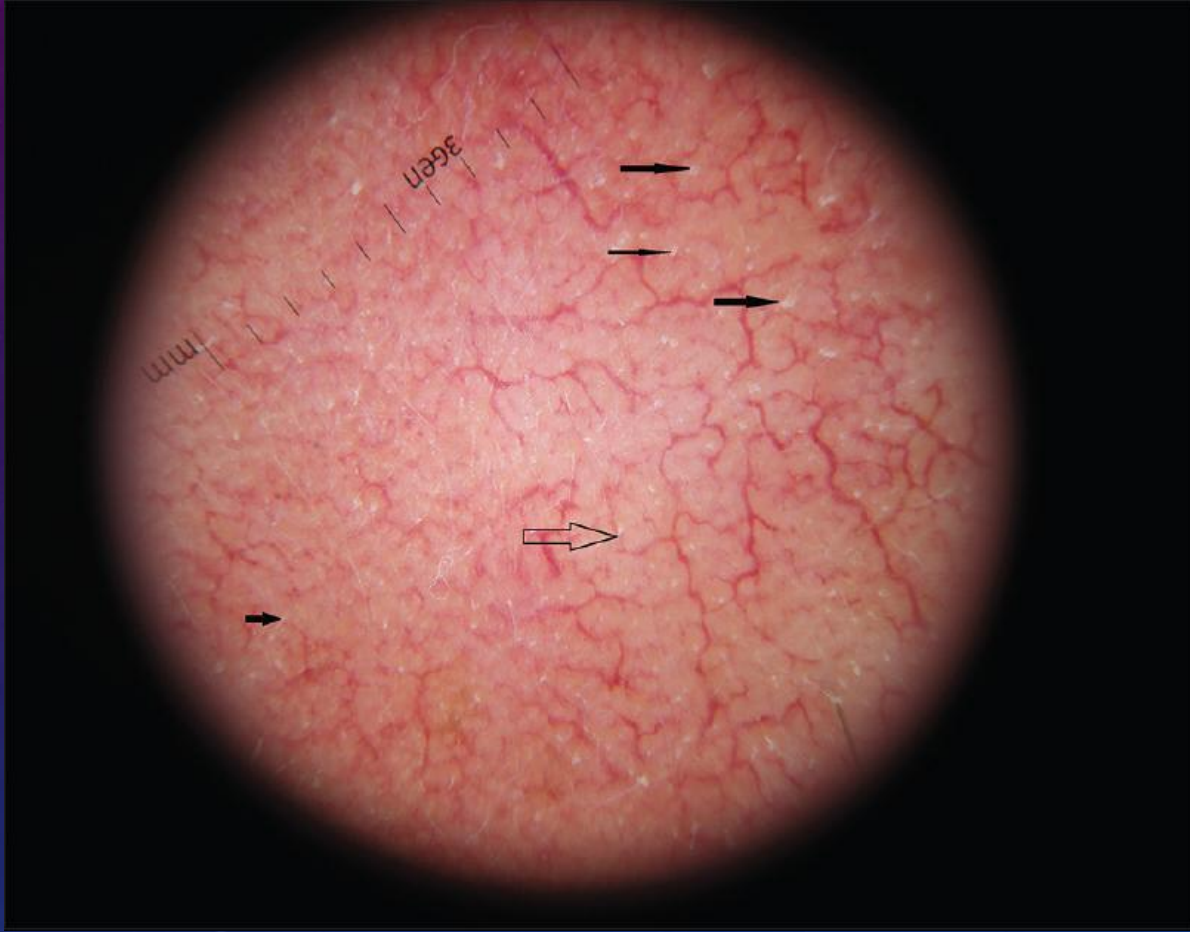
Rozasede dermatoskopi



Foliküler
püstüller

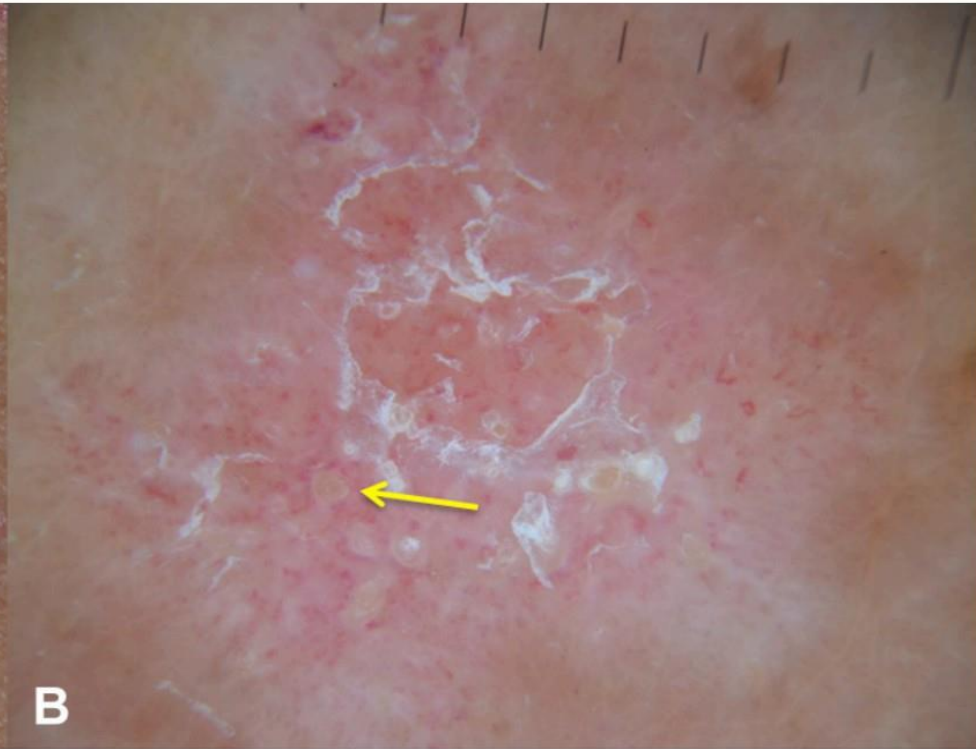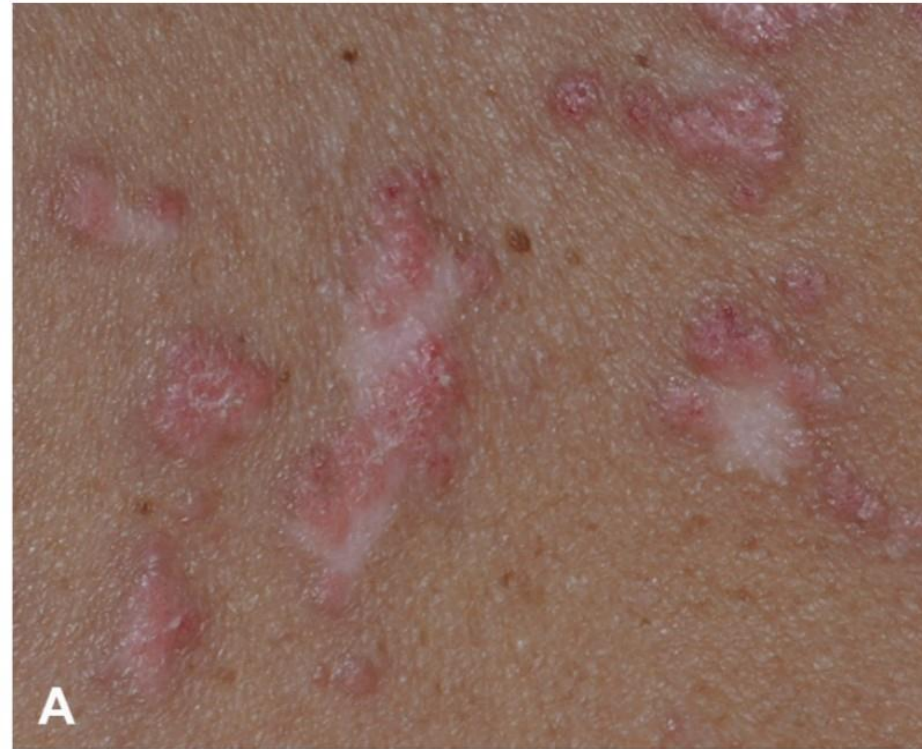- Eritemli telenjektatik rozase: Retiküler dağılımlı lineer poligonal damarlar
- Papülopüstüler rozase: Foliküler tıkaçlar, foliküler püstüller, poligonal damarlar

Demodikozis



- Yarım ay şeklinde beyaz-sarı renkli tıkaçlar şeklinde görülen *Demodex* kuyrukları, poligonal damar yapıları

Diskoid Lupus Eritematozus



Dermoscopic criteria

Perifollicular whitish halo
Follicular keratotic plugs
Telangiectatic vessels
White scales
Pigmentation
Structureless whitish areas
Follicular red dots

Histopathological criteria

Perifollicular fibrosis
Follicular hyperkeratosis
Telangiectasias
Hyperkeratosis
Pigmentary incontinence
Diffuse dermal fibrosis
Perifollicular red blood cell extra

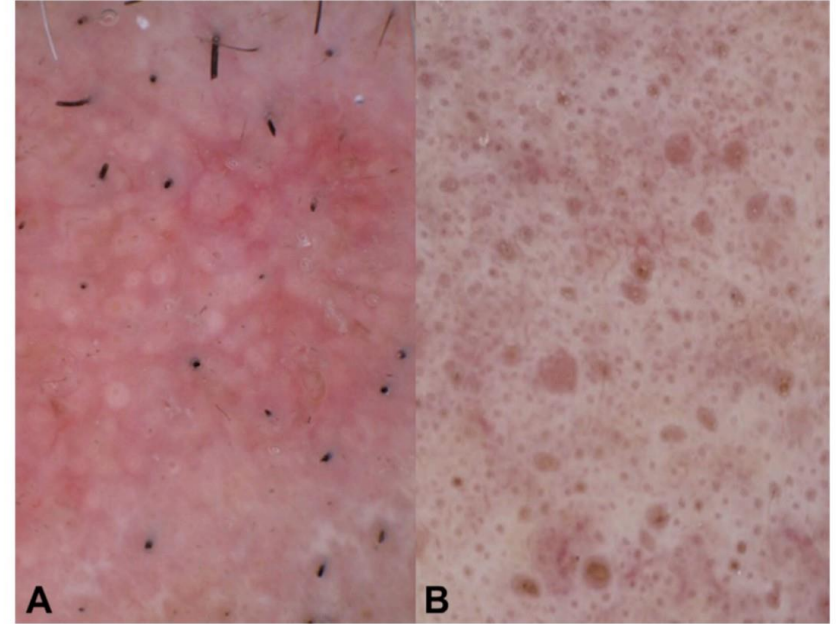
- Hiperkeratozu yansıtan beyaz skuamlar
- Perifoliküler fibrozisi yansıtan perifoliküler beyaz halo
- Foliküler hiperkeratozu yanından foliküler keratotik tıkaçlar
- Difüz dermal fibrozisi yansıtan yapısız beyaz alanlar
- Lineer, noktasal damarlar

Diskoid Lupus Eritematozus

Table 4 Mean duration of discoid lupus erythematosus in relation to prevalence of each dermoscopic criterion

| Dermoscopic criteria | Mean disease duration (months) | P-value |
|-----------------------------|--------------------------------|---------|
| Perifollicular whitish halo | | |
| Present | 7.68 ± 4.74 | < 0.01 |
| Absent | 18.18 ± 6.30 | |
| Follicular keratotic plugs | | |
| Present | 8.95 ± 5.24 | 0.013 |
| Absent | 15.00 ± 8.83 | |
| Telangiectatic vessels | | |
| Present | 13.38 ± 6.85 | < 0.01 |
| Absent | 8.19 ± 6.56 | |
| White scales | | |
| Present | 9.13 ± 2.33 | 0.09 |
| Absent | 11.60 ± 8.19 | |
| Pigmentation | | |
| Present | 15.79 ± 5.94 | < 0.01 |
| Absent | 7.16 ± 5.59 | |
| Structureless whitish areas | | |
| Present | 17.25 ± 6.27 | < 0.01 |
| Absent | 7.31 ± 4.71 | |
| Follicular red dots | | |
| Present | 6.95 ± 4.95 | < 0.01 |
| Absent | 13.20 ± 7.27 | |

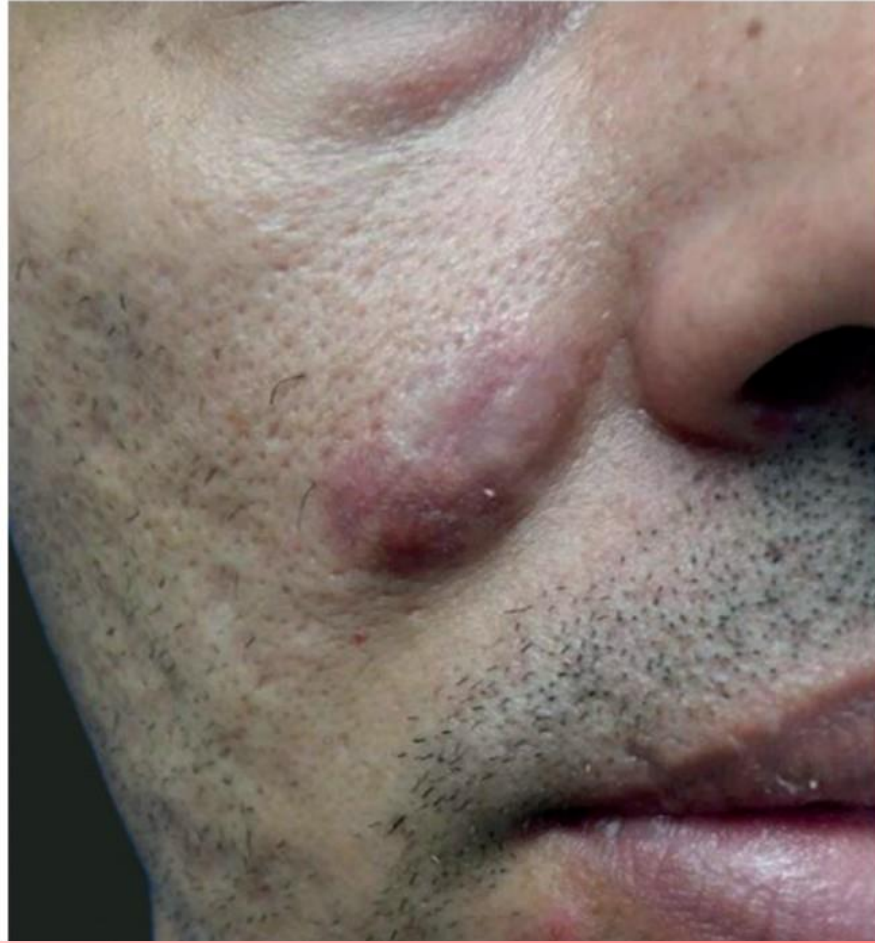Data are mean ± SD.



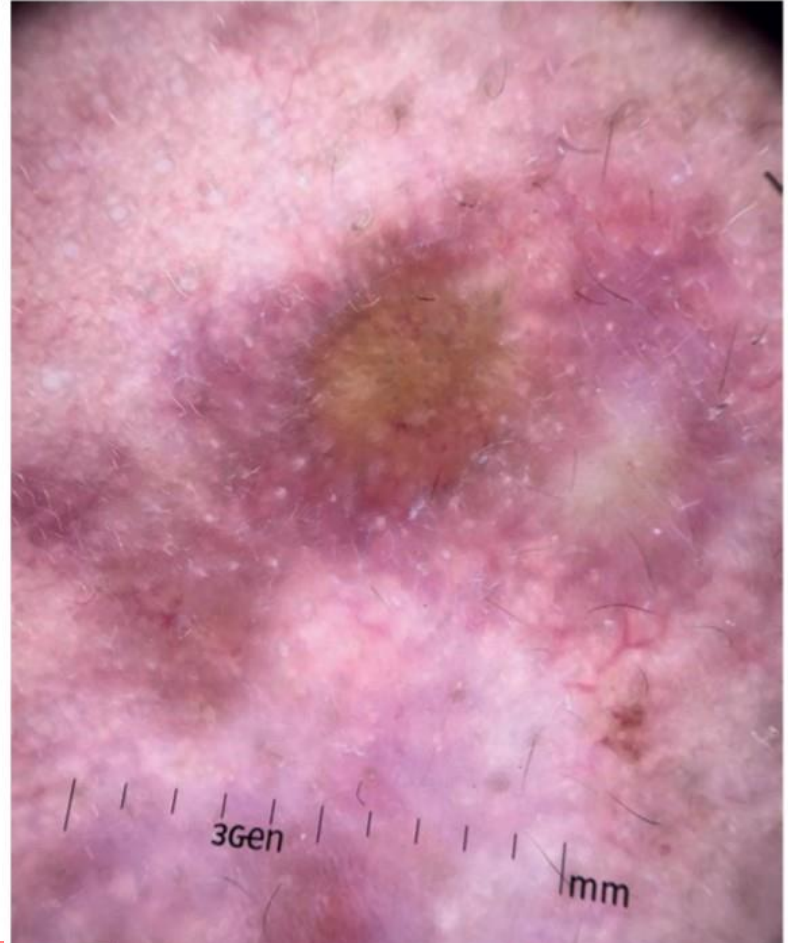
Hastalık süresine göre dermatoskopik bulgular değişmekte

- Erken evrede perifoliküler beyaz halo, foliküler keratotik tıkaçlar, beyaz skuam yapıları, ve foliküler kırmızı noktalar daha sık
- Hastalık süresi uzadıkça telenjektazik damarlar, pigmentasyon ve yapısız beyaz alanlar artmakta

Granüloma fasiiale



- Gri zemin
- Beyaz çizgiler



- Sarı-kahverengi yapısız alanlar
- Düzensiz dallanan damarlar

Yüzde İnflamatuvar Deri Hastalıklarında Dermatoskopik İpuçları

Table 2 Frequency of dermoscopic criteria in each disease

| | SD (n = 22) | ER (n = 25) | SAR (n = 19) | LV (n = 16) | DLE (n = 28) | GF (n = 5) |
|-----------------------------|-------------------|------------------|-------------------|-------------------|-------------------|-----------------|
| Dotted vessels | 19 (86.4%) | 0 | 1 (5.3%) | 0 | 1 (3.6%) | 0 |
| Linear branching vessels | 1 (4.5%) | 4 (16%) | 14 (73.7%) | 15 (93.8%) | 15 (53.6%) | 5 (100%) |
| Vascular polygons | 0 | 25 (100%) | 0 | 0 | 0 | 0 |
| Orange-yellowish areas | 2 (9.1%) | 3 (12%) | 16 (84.2%) | 15 (93.8%) | 0 | 0 |
| Whitish structureless areas | 1 (4.5%) | 0 | 3 (15.8%) | 0 | 9 (32.1%) | 0 |
| Perifollicular whitish halo | 0 | 0 | 0 | 0 | 19 (67.9%) | 3 (60%) |
| Follicular plugs | 2 (9.1%) | 6 (24%) | 5 (26.3%) | 1 (6.2%) | 19 (67.9%) | 1 (20%) |
| Dilated follicles | 0 | 4 (16%) | 3 (15.8%) | 0 | 14 (50%) | 5 (100%) |
| Pigmentation structures | 0 | 1 (4%) | 8 (42.1%) | 2 (12.5%) | 12 (42.9%) | 2 (40%) |
| Whitescales | 6 (27.3%) | 7 (28%) | 4 (21.1%) | 4 (25%) | 9 (32.1%) | 0 |
| Yellow scales | 17 (77.3%) | 4 (16%) | 2 (10.5%) | 0 | 1 (3.6%) | 1 (20%) |

Numbers in parentheses represent percentages (%). SD, seborrheic dermatitis; LV, lupus vulgaris; GF, granuloma faciale; ER, erythematotelangiectatic rosacea.

The commonest dermoscopic criteria of each disease are marked in bold.

- Sarı skuamlar → Seboreik dermatit
- Poligonal damarlar → Rozase
- Foliküler tıkaç yapıları ve perifoliküler beyaz halo → DLE
- Dilate foliküller ve perifoliküler halo → Granüloma fasiyale

Eve Götürülecekler

- İnflamatuvar hastalıklarda dermoskopi ile ilgili net sınıflandırma yok
- Klinik ile birlikte değerlendirilmeli
- Temel olan iki patern: Damar ve skuam morfolojileri
- Tanıya spesifik ip uçları
- Bulguların hastalık evresine göre değişebileceği akılda tutulmalı



İlginiz için teşekkürler..