

Dolgu ile Alt Yüz Şekillendirme



Dr. DİLEK BAŞARAN
Dermatoloji Uzmanı



Keskin çene hattı

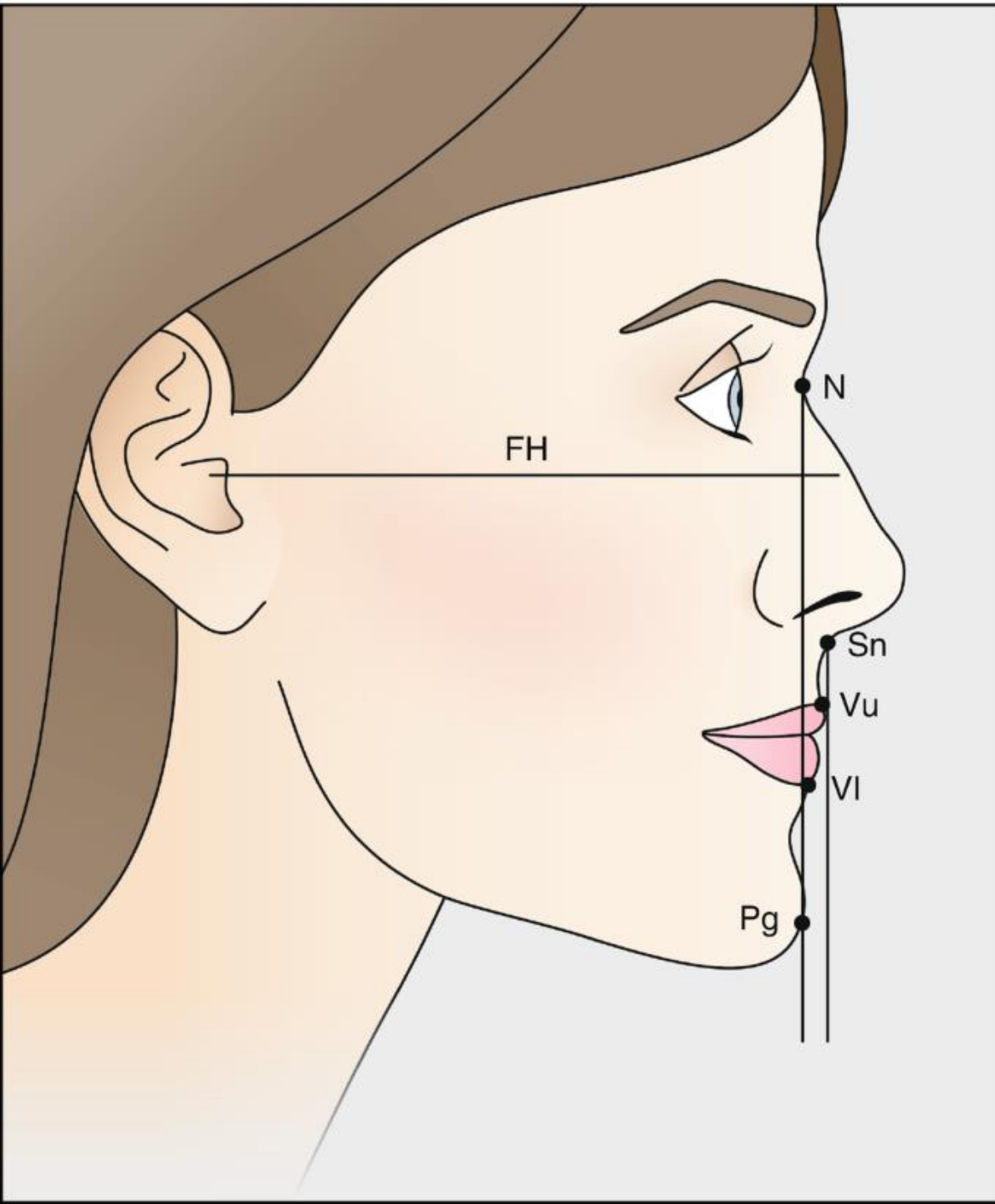
THE
SKIN HEALTH
INSTITUTE

THE POWER OF A CHIN

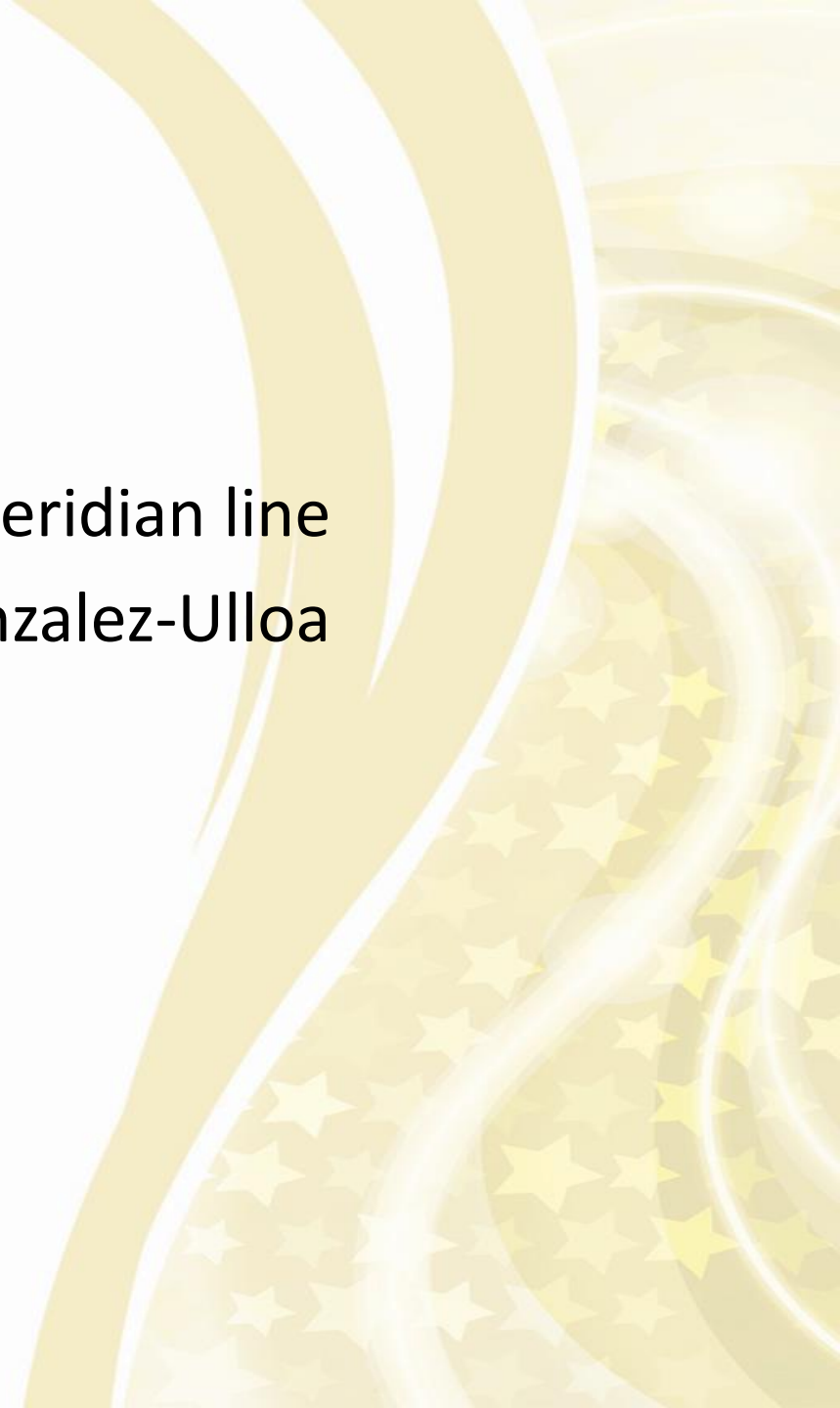WITH CHIN

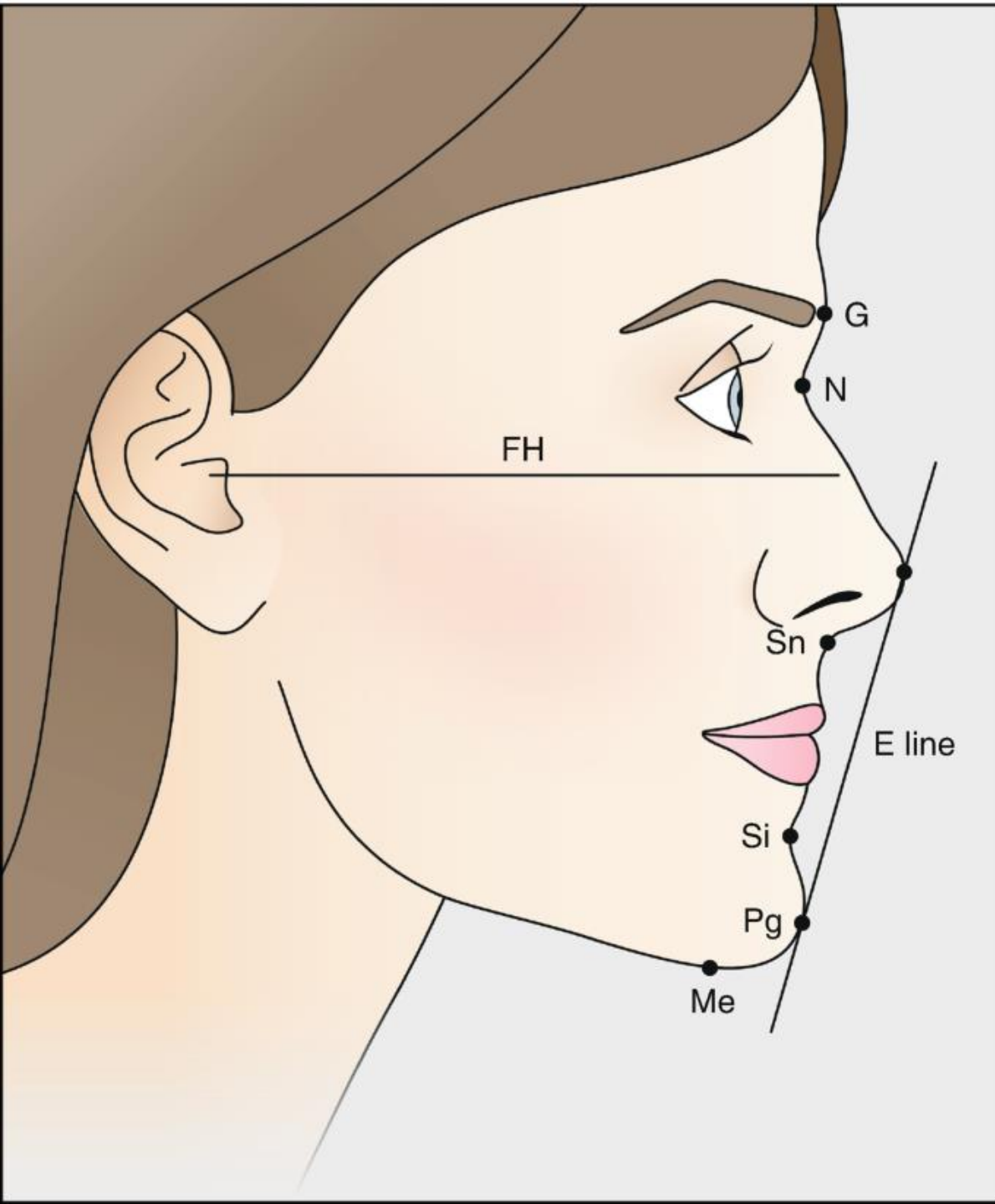
WITHOUT CHIN



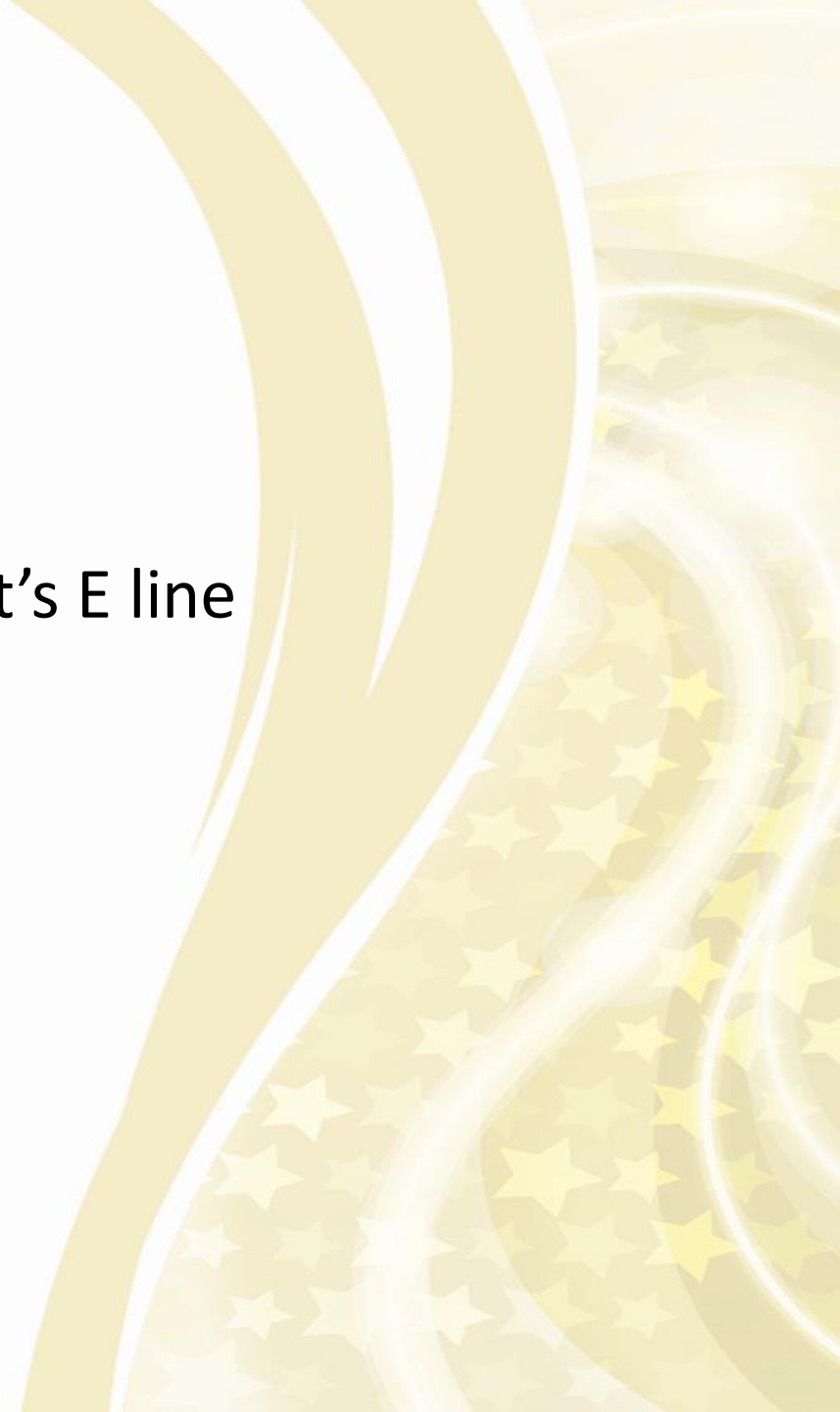


- Zero meridian line
- Gonzalez-Ulloa

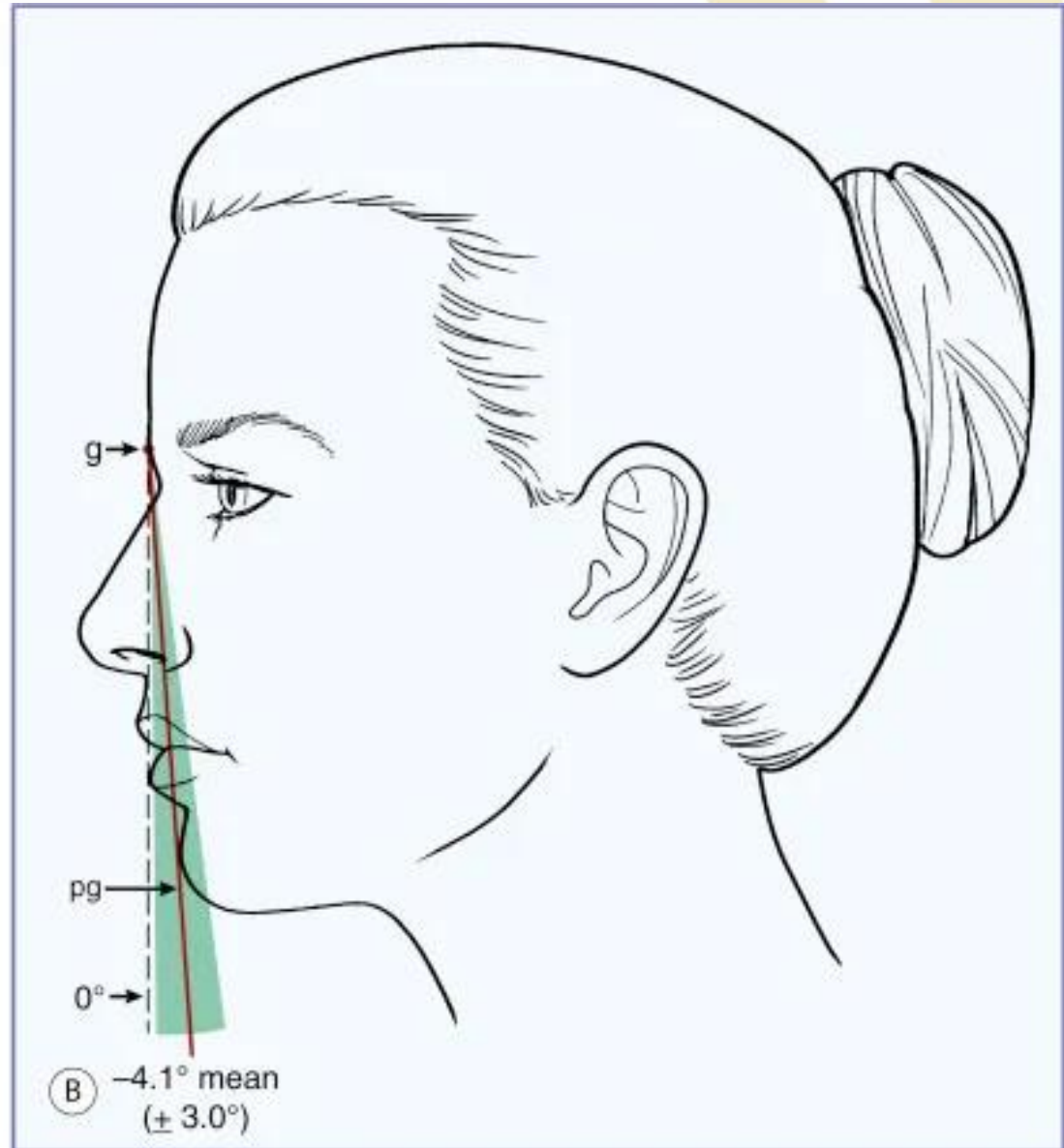
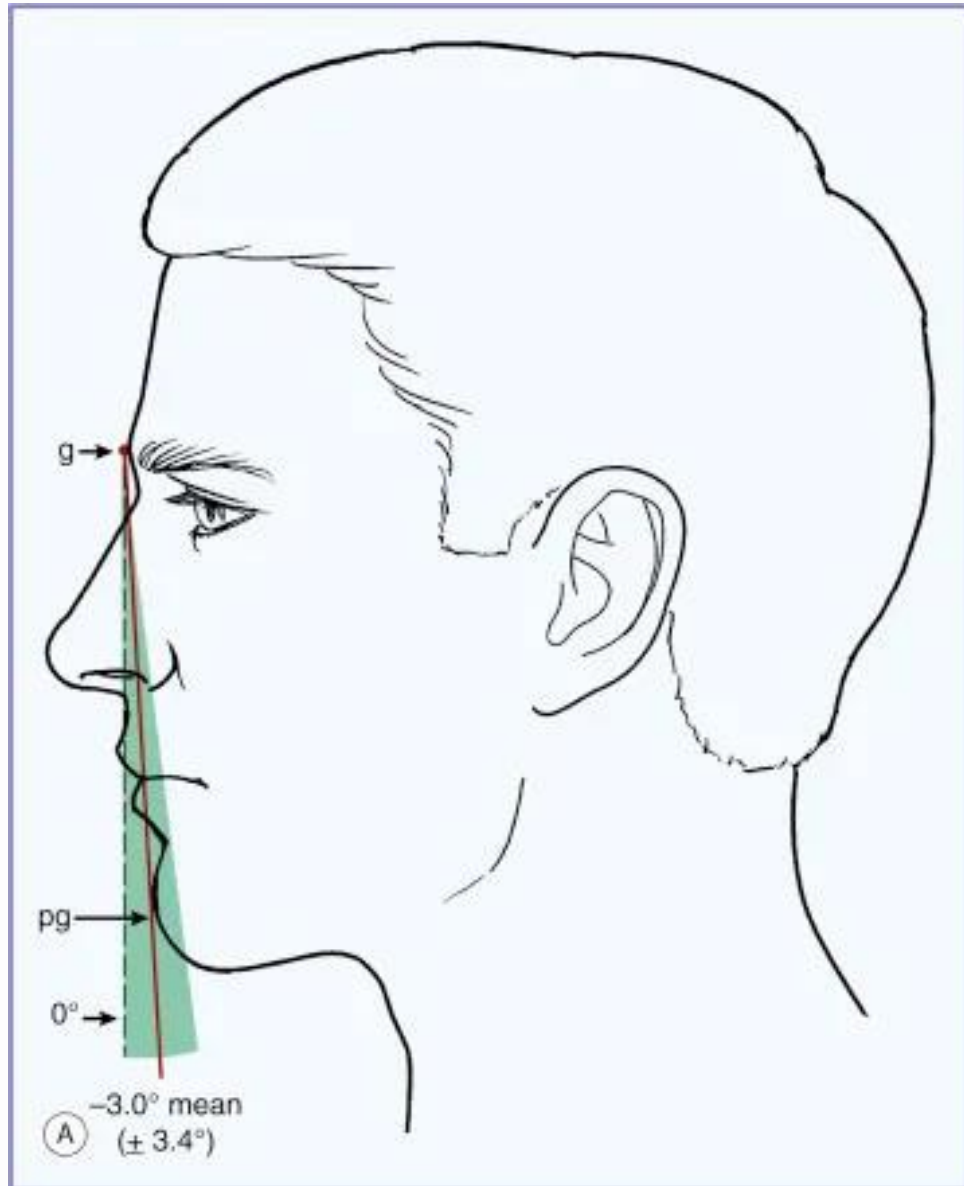


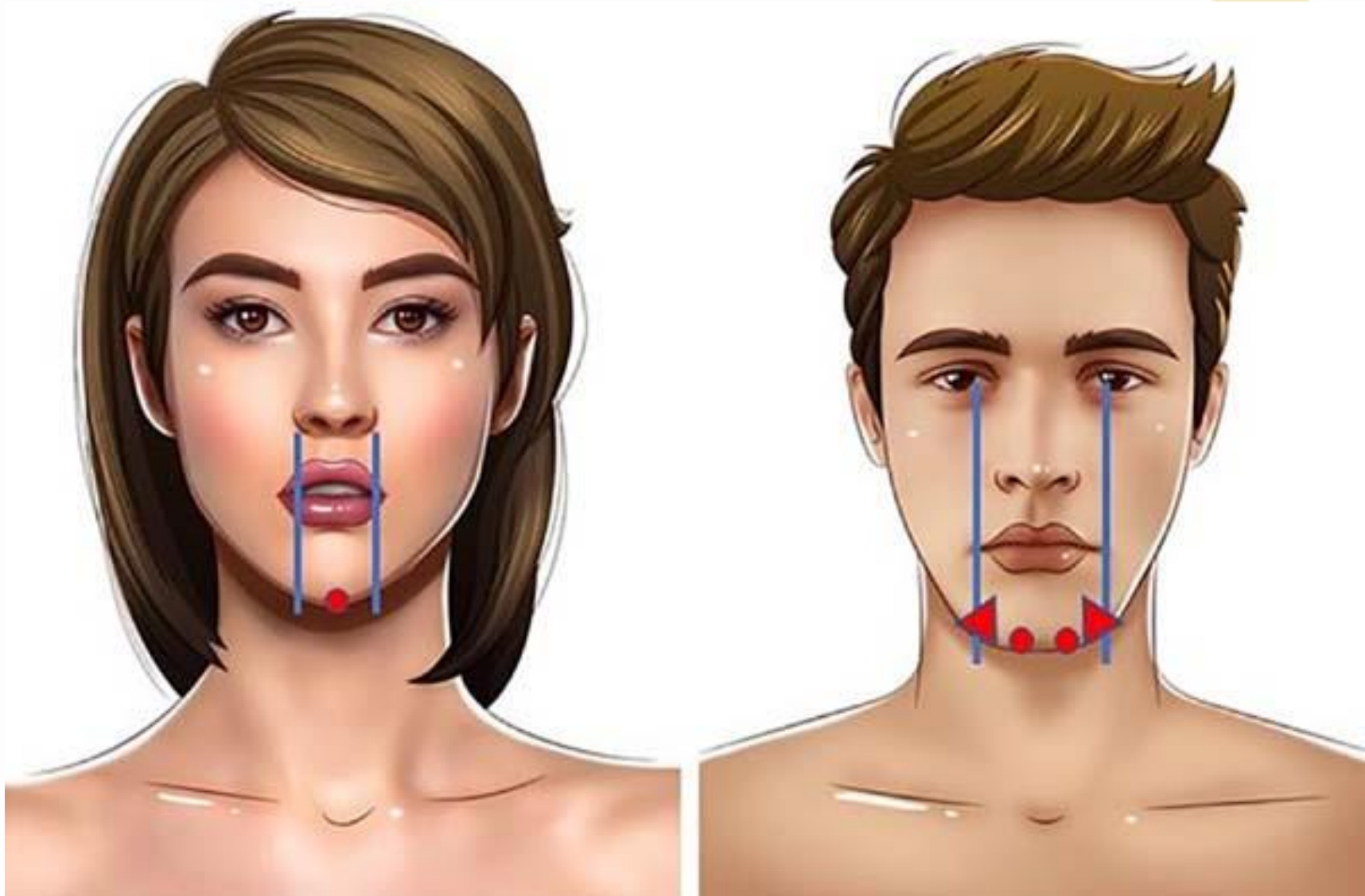


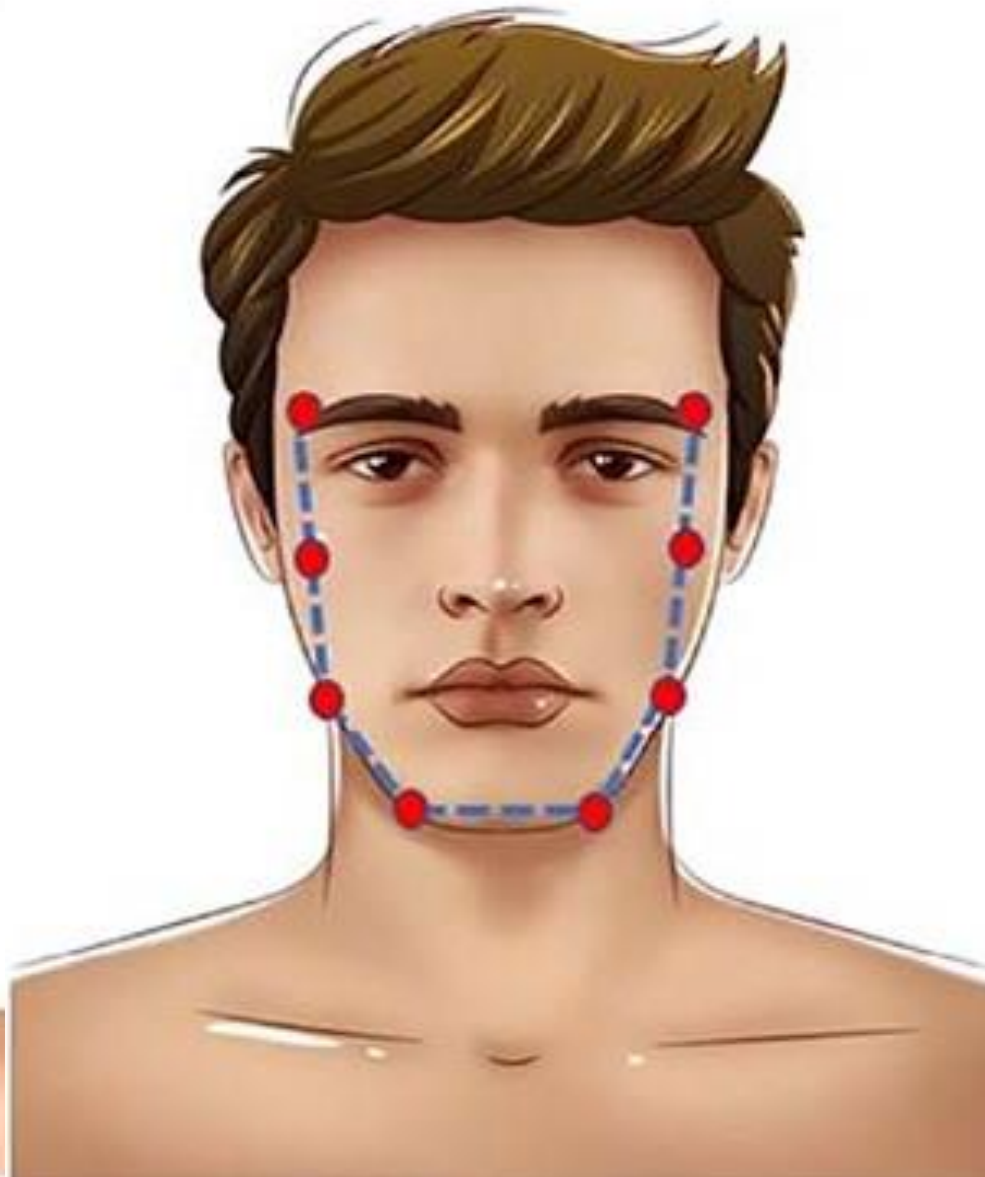
- Rickett's E line

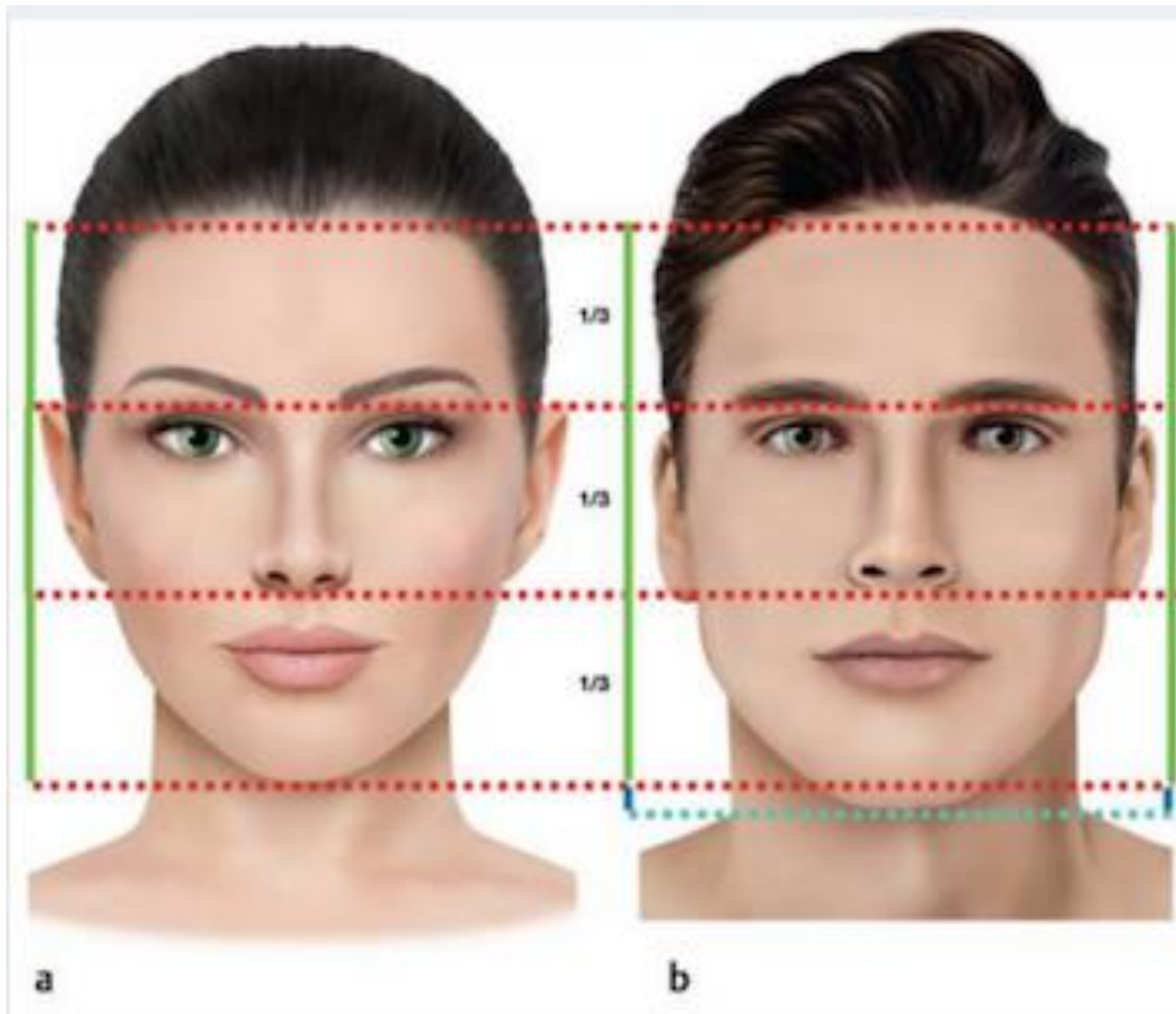


- Farkas et al. 1994











You should shave.
I'm sure it will
look good.

Ok



20 minutes later



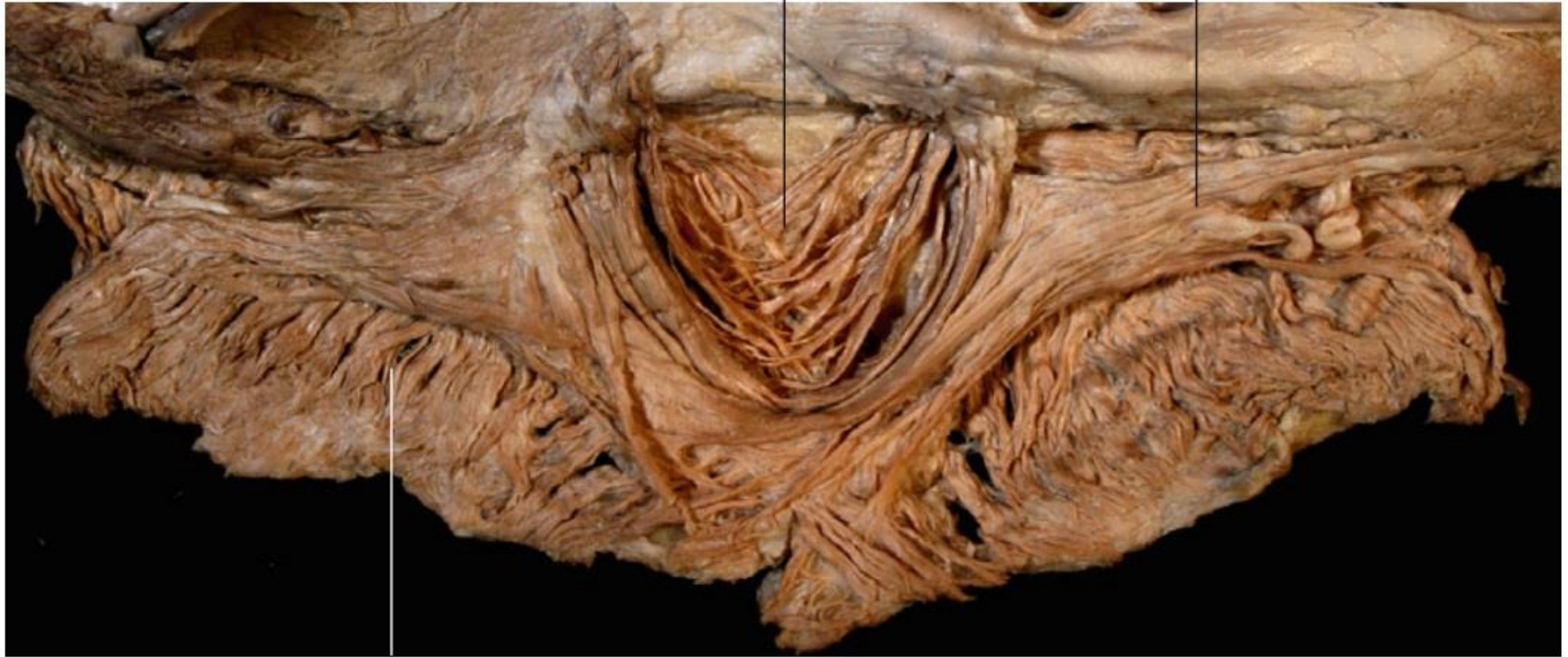Oh, you shaved



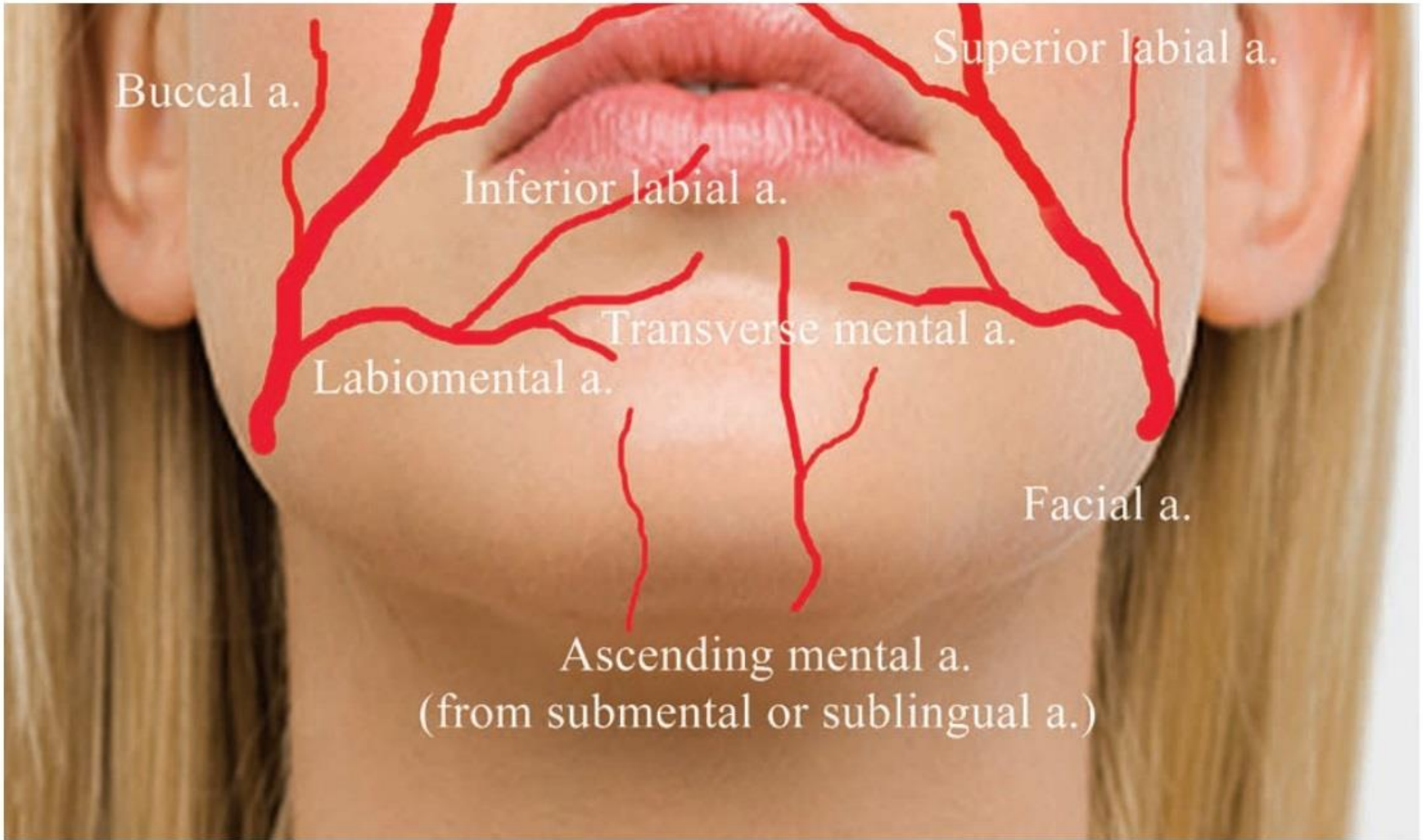
Yes.

Mentalis m.

Incisive labii inferioris m.



Depressor labii inferioris m.



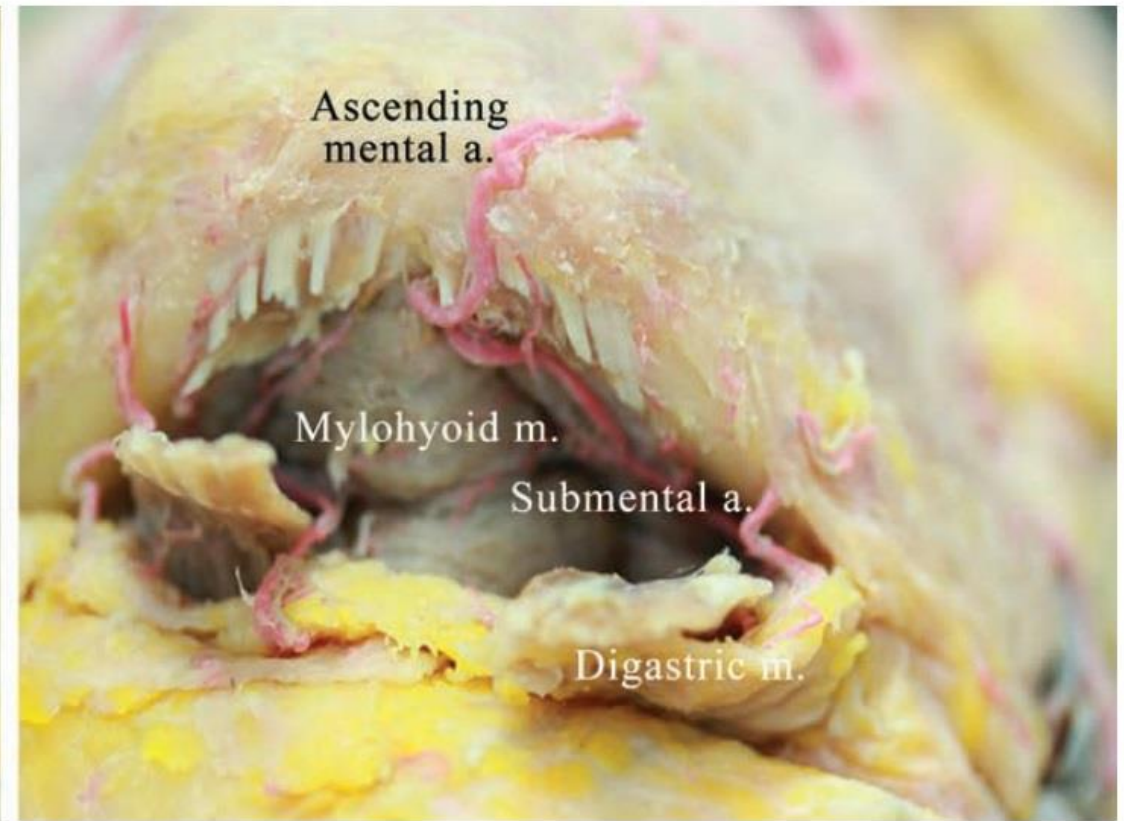
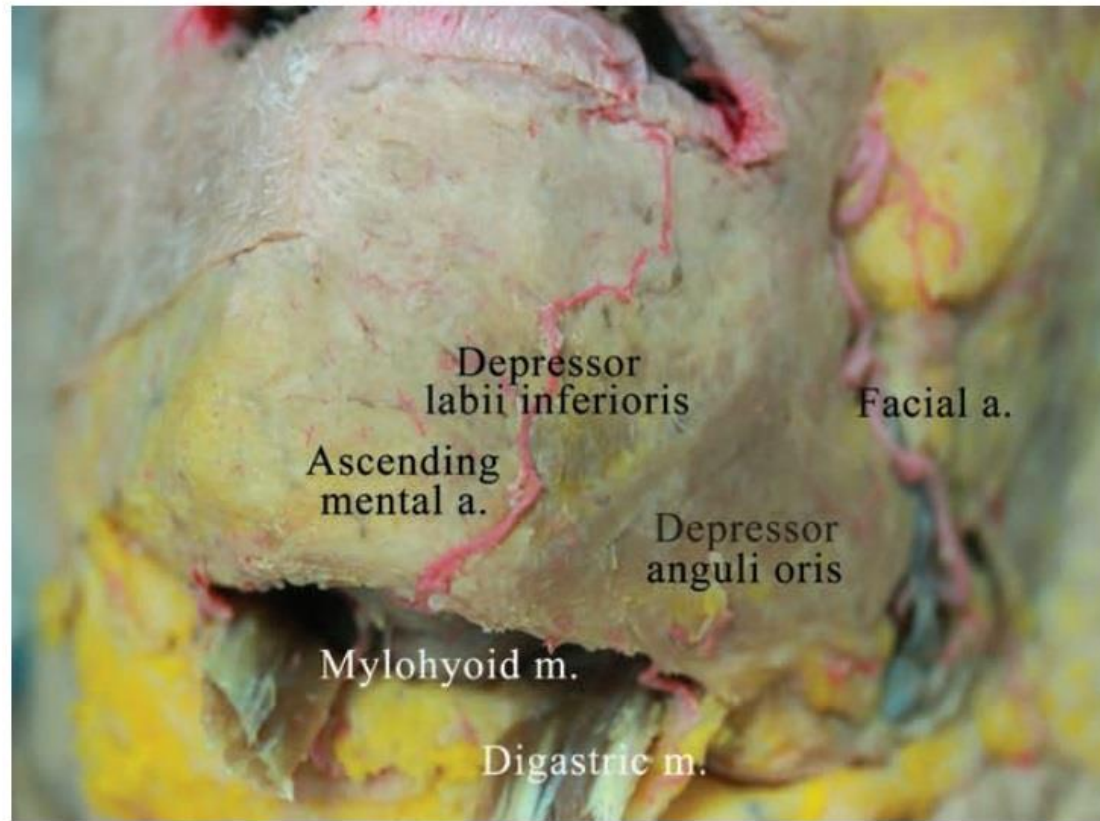
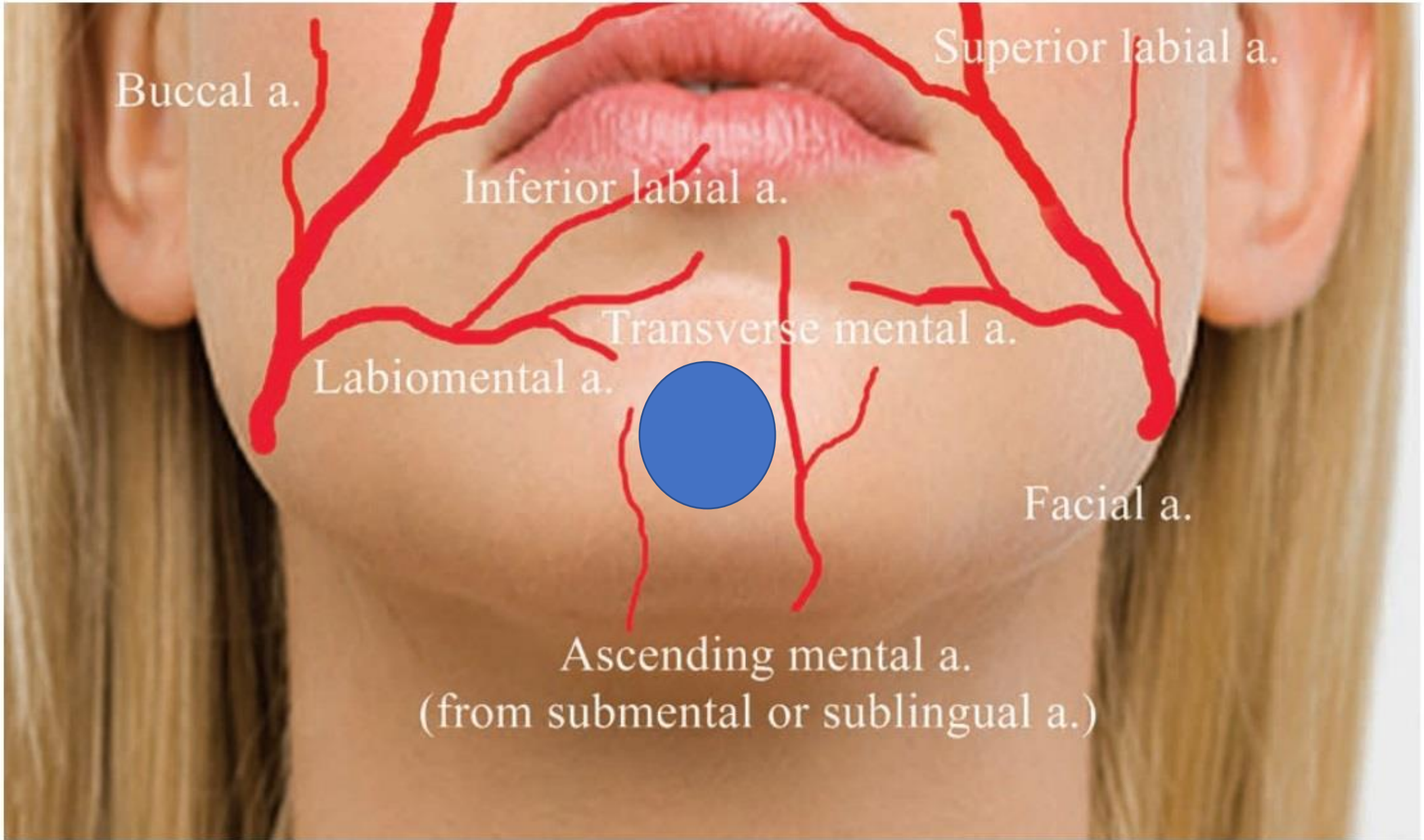


Fig. 1. The dominant ascending mental artery entered the chin as a terminal branch of the submental artery.



Buccal a.

Superior labial a.

Inferior labial a.

Transverse mental a.

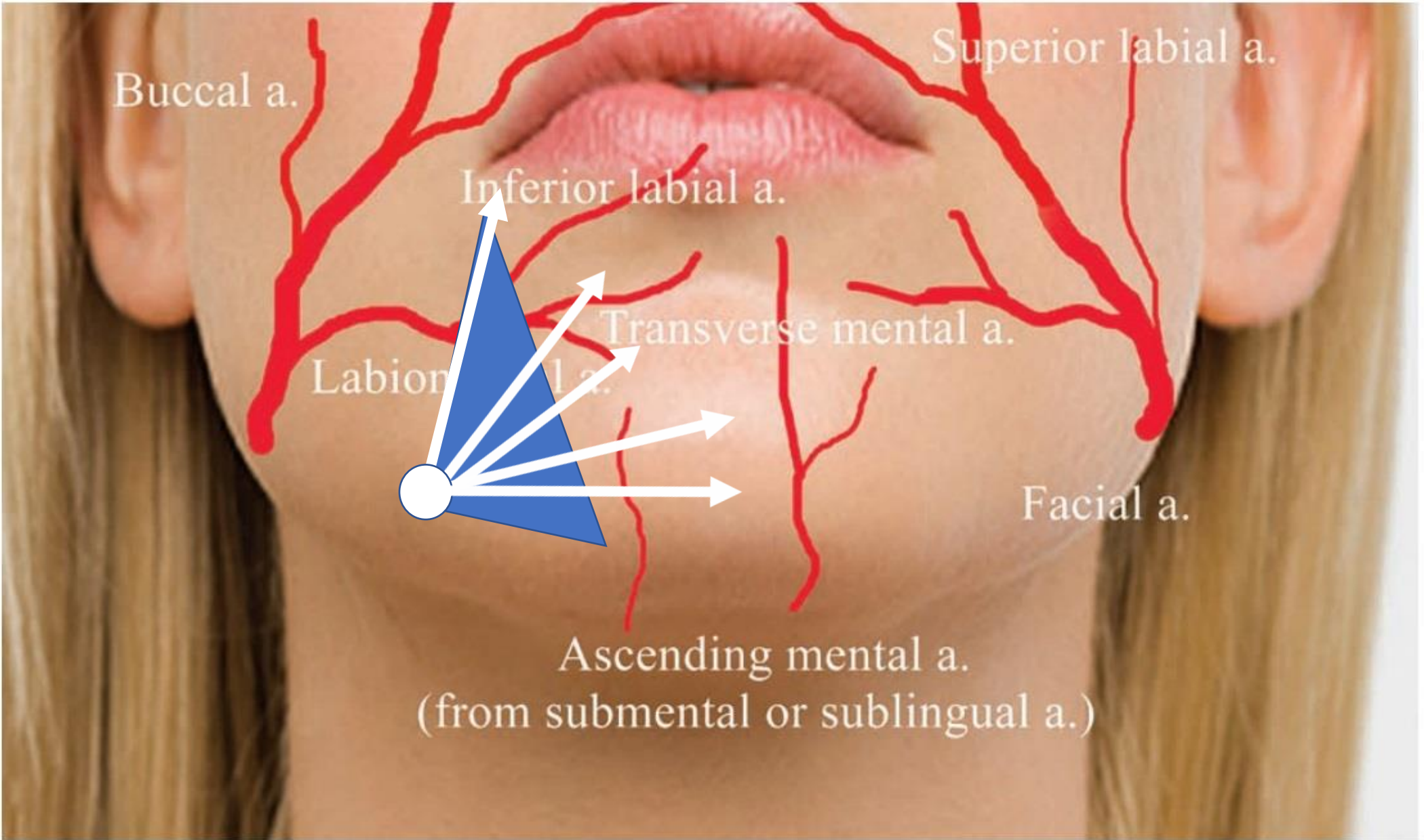
Labiomentental a.

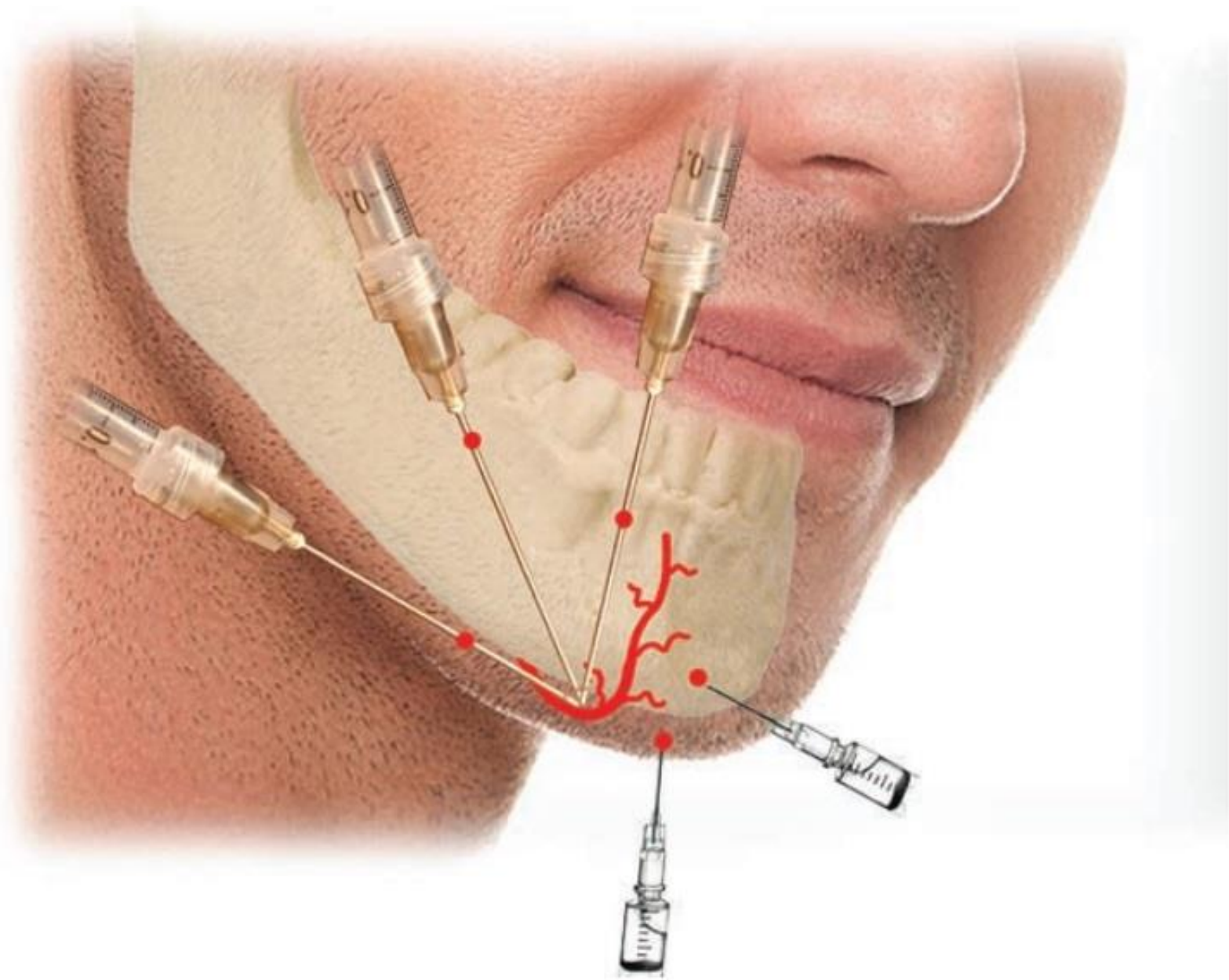
Facial a.

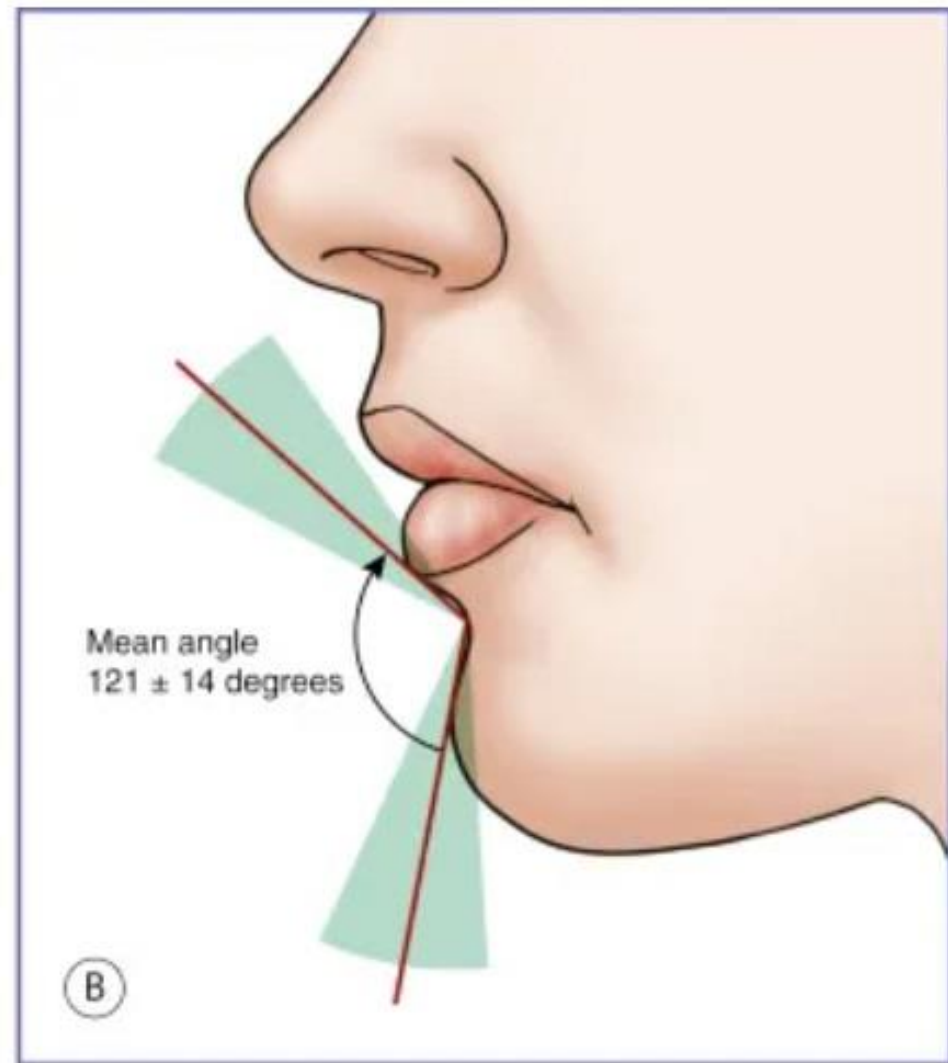
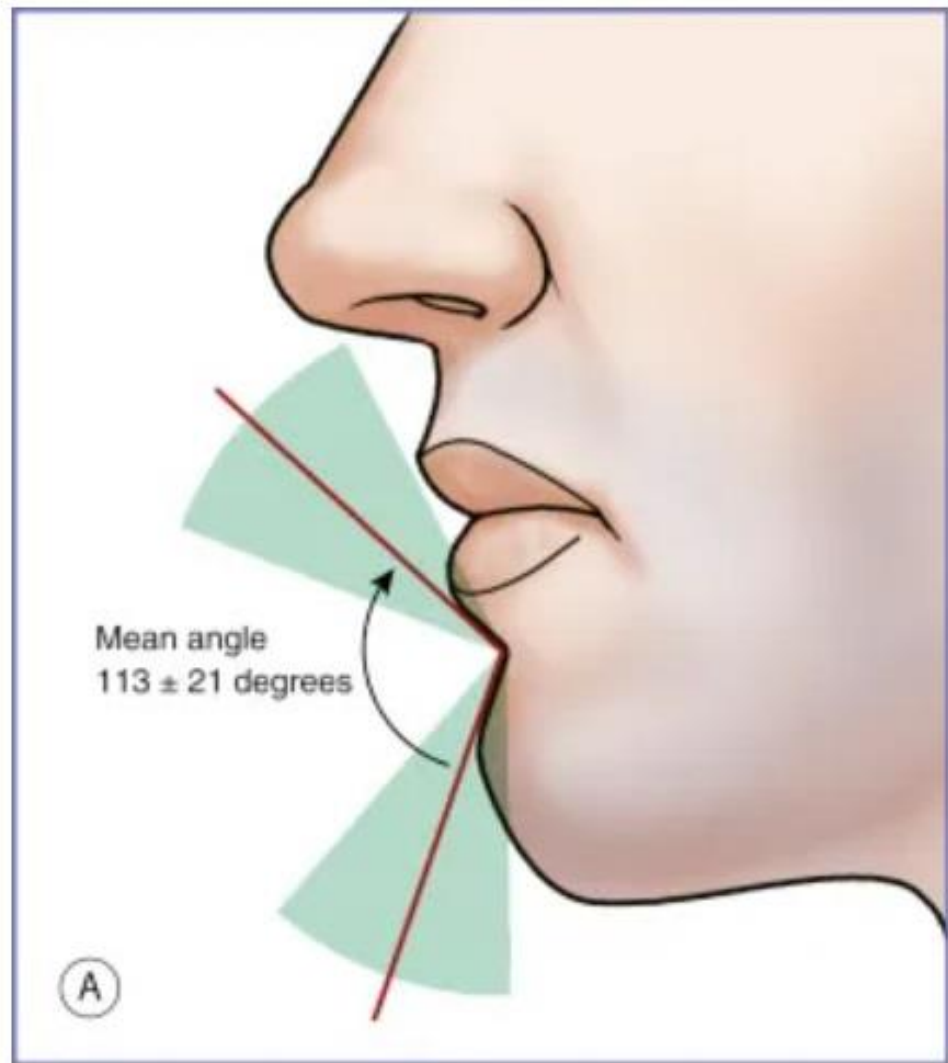
Ascending mental a.

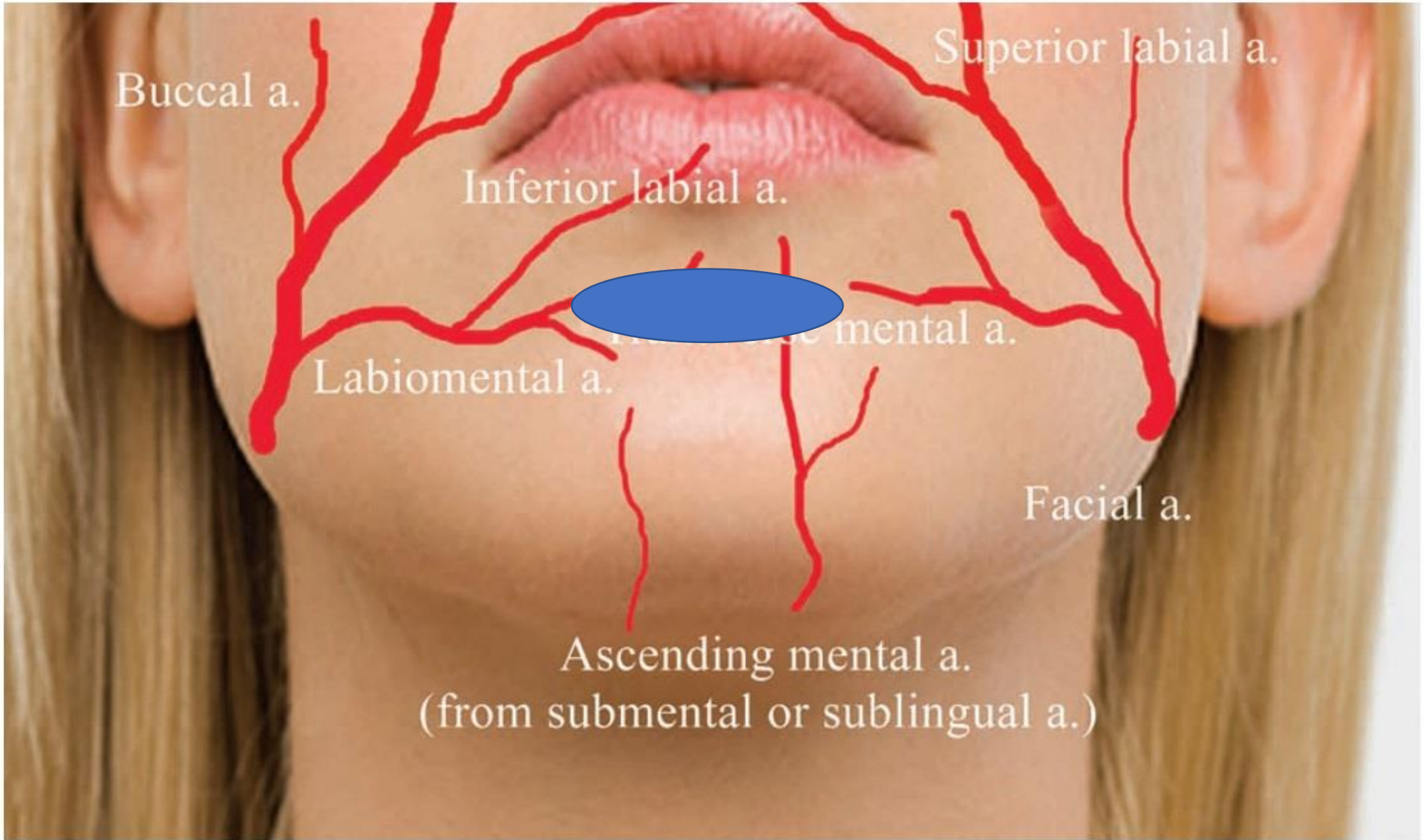
(from submental or sublingual a.)

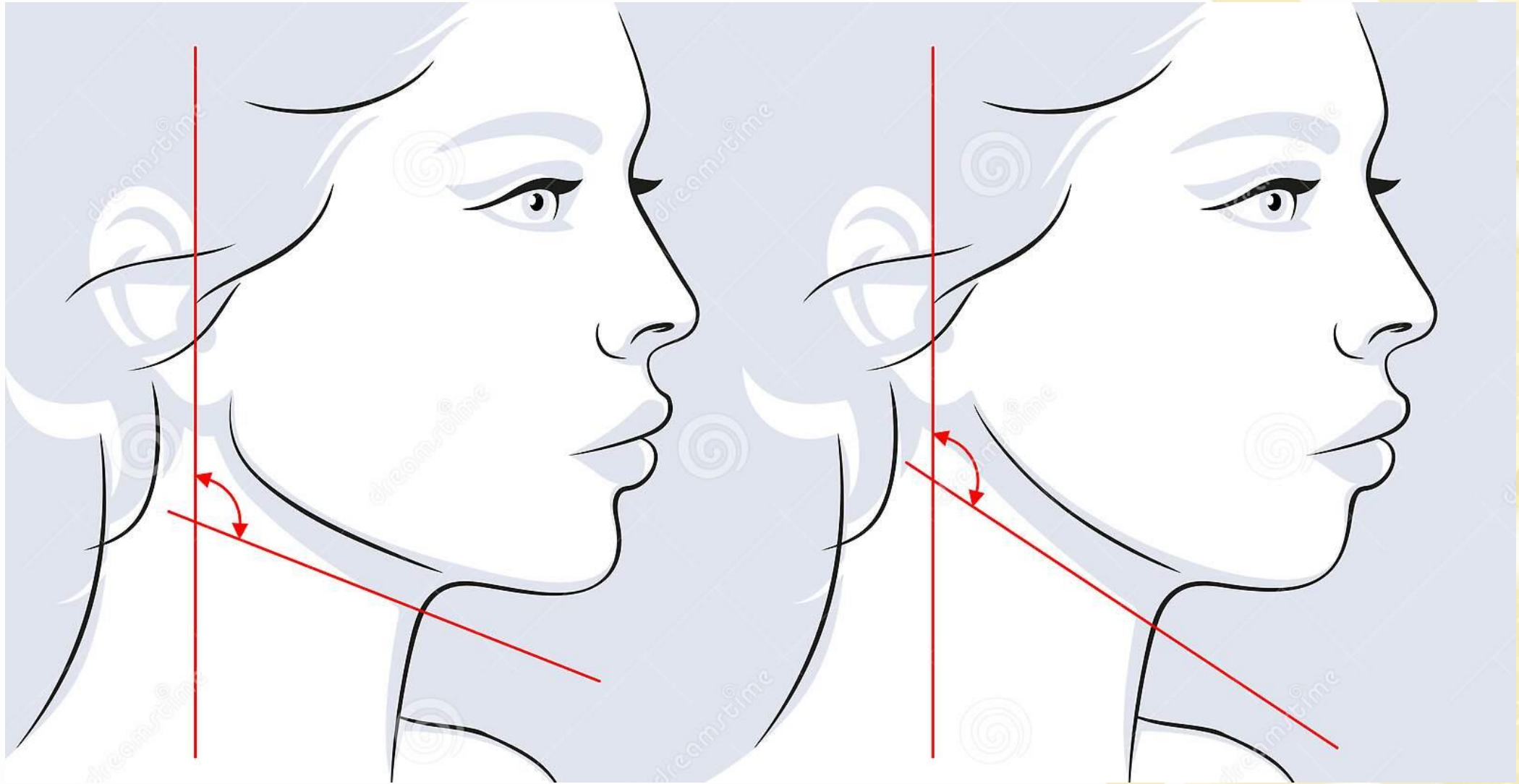










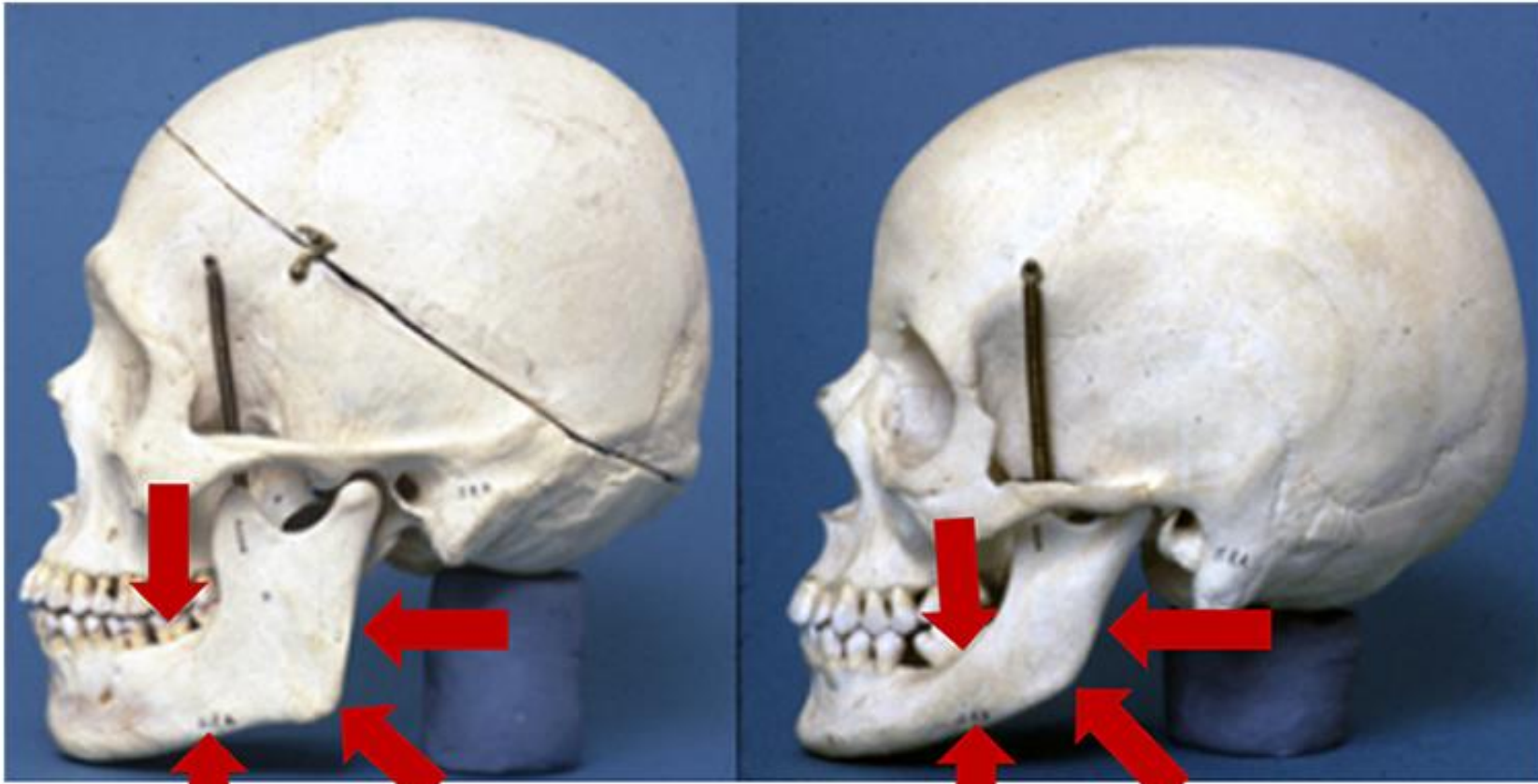


BEFORE



AFTER

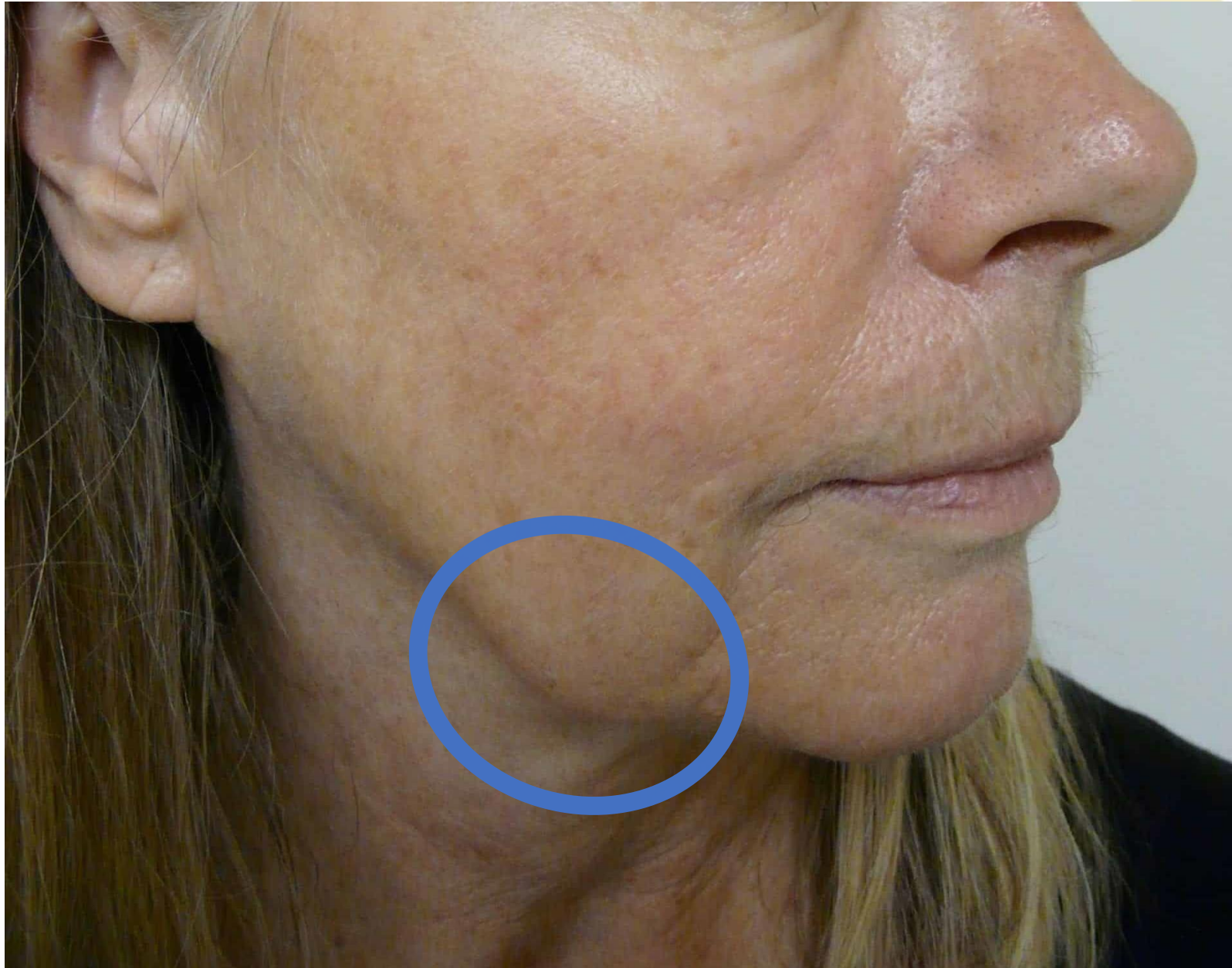

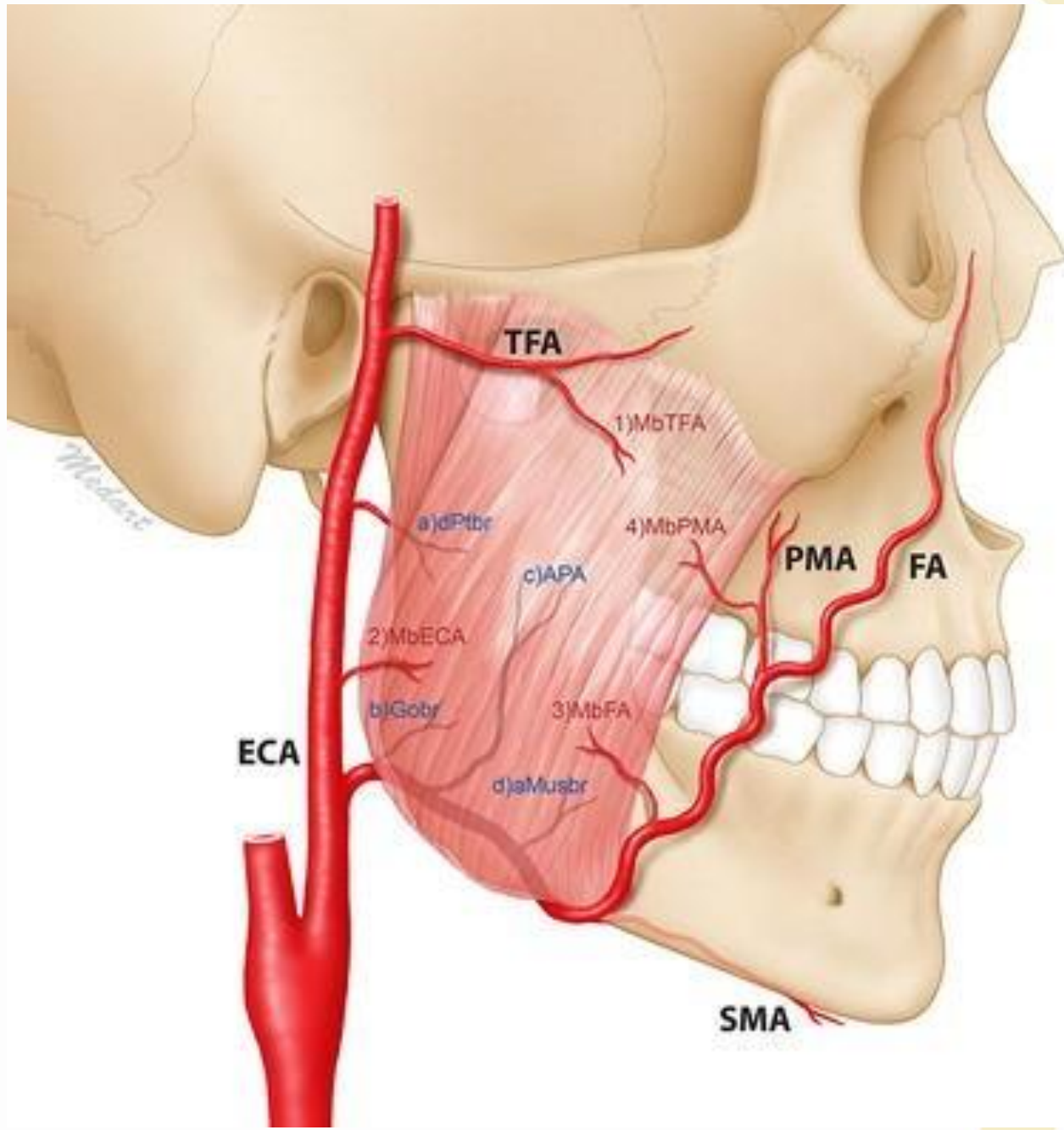


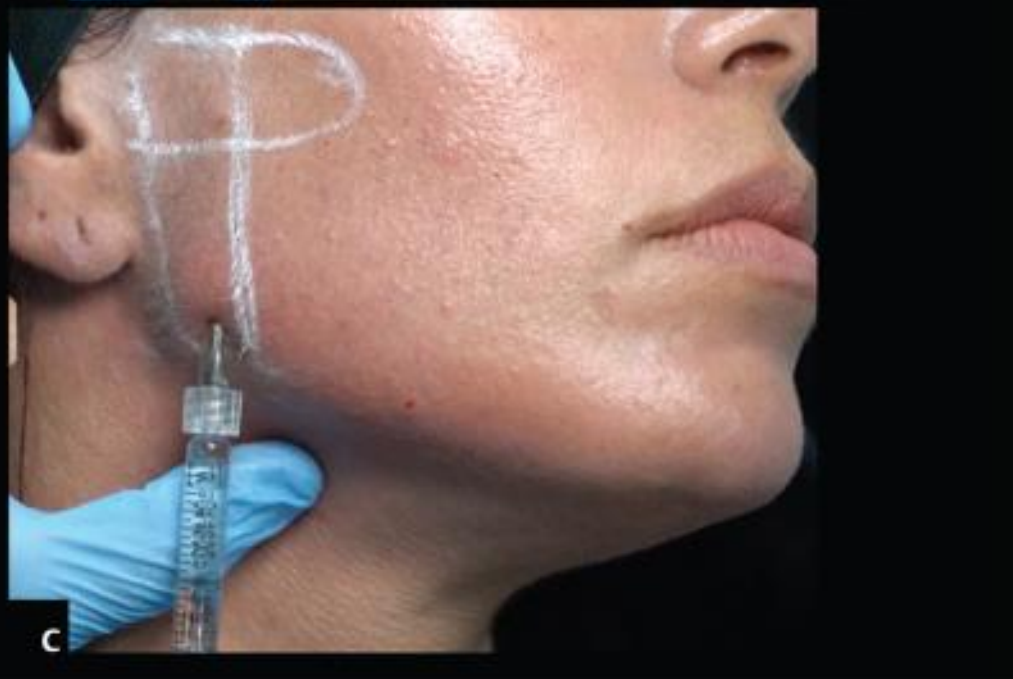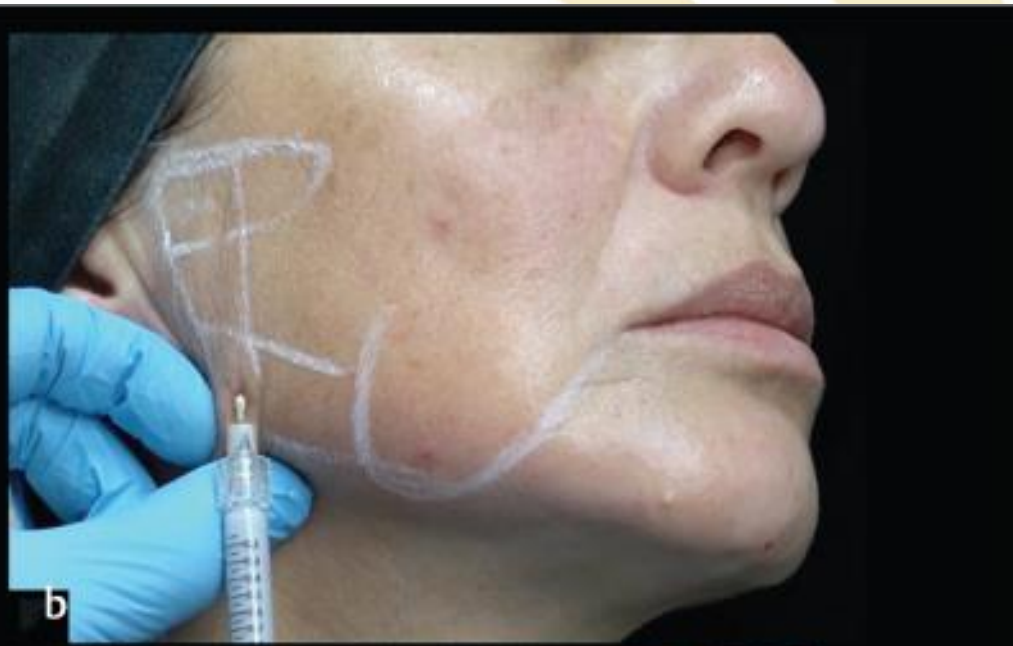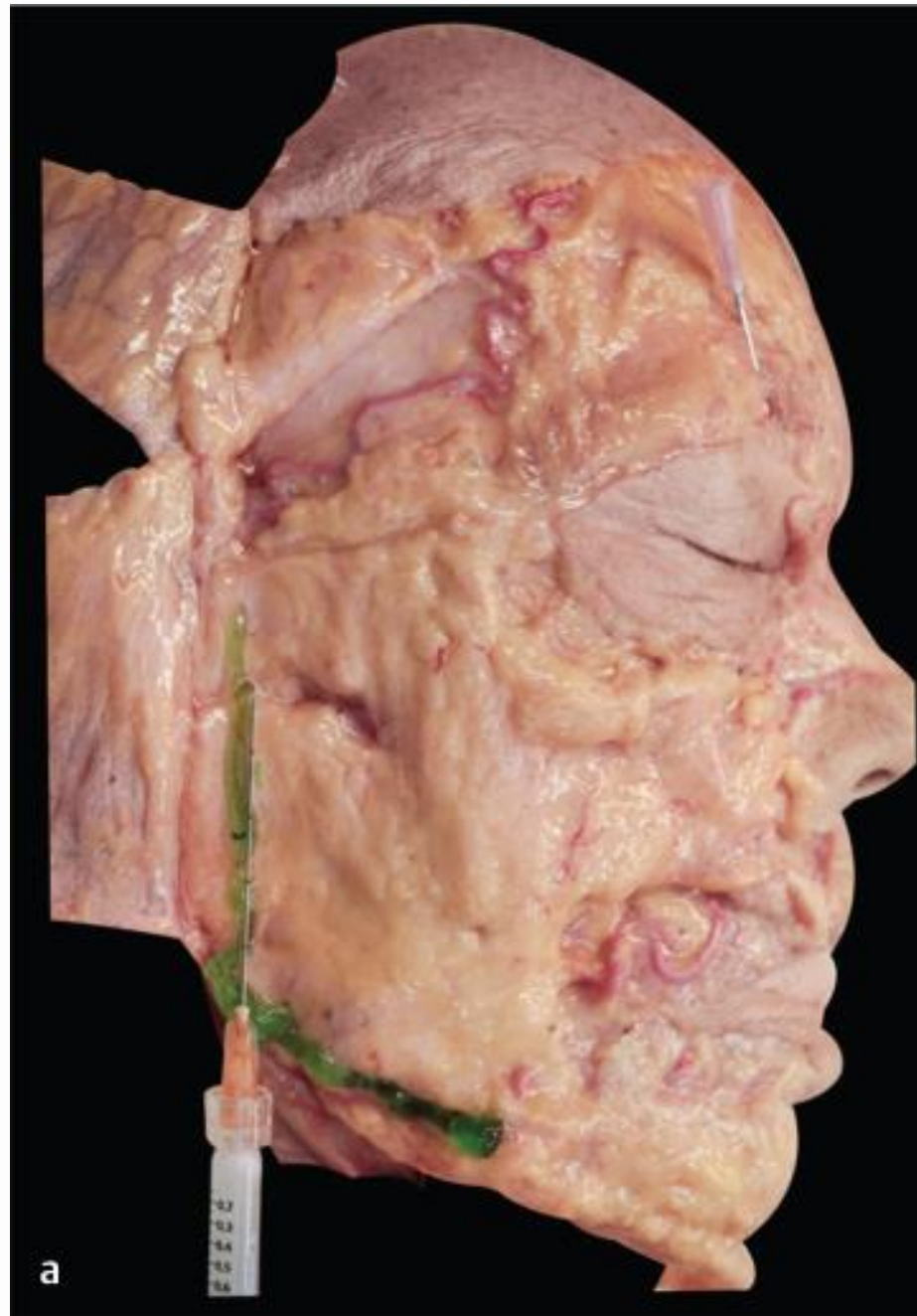
100-120 derece

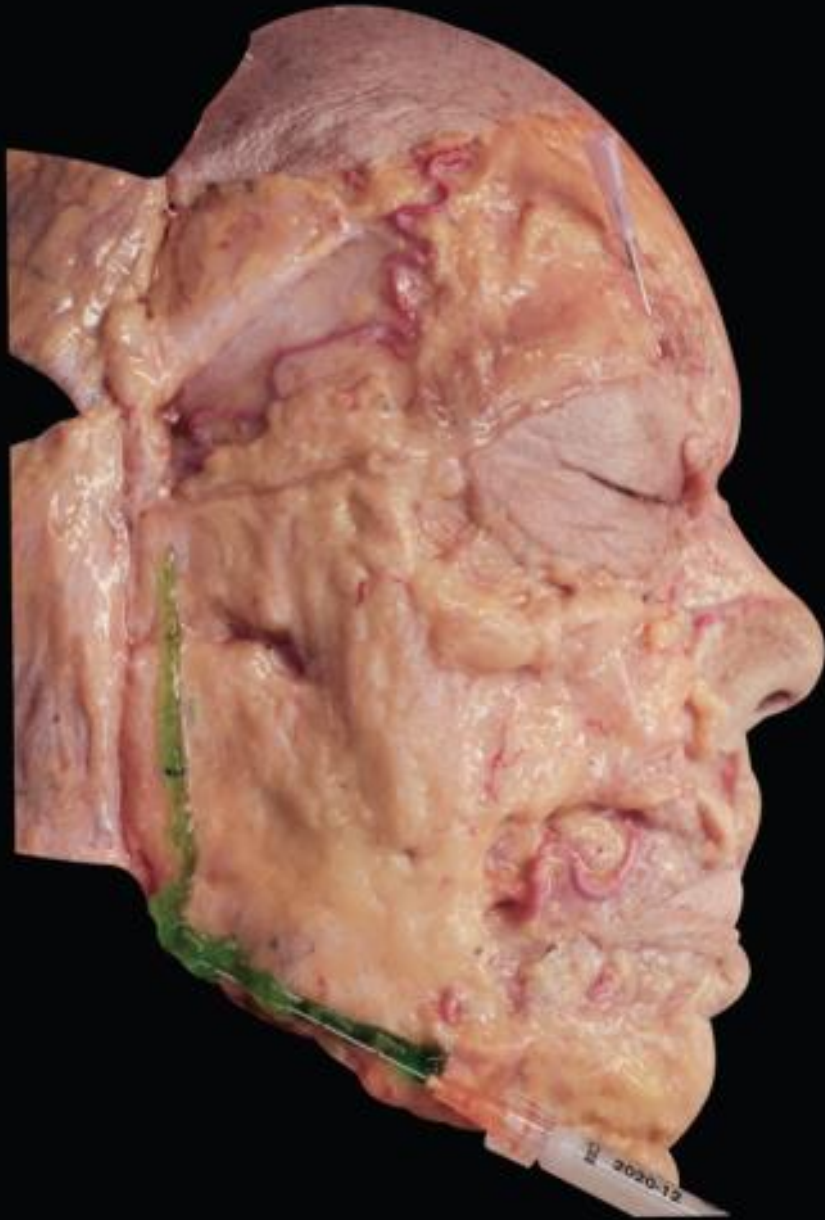120-140 derece

«

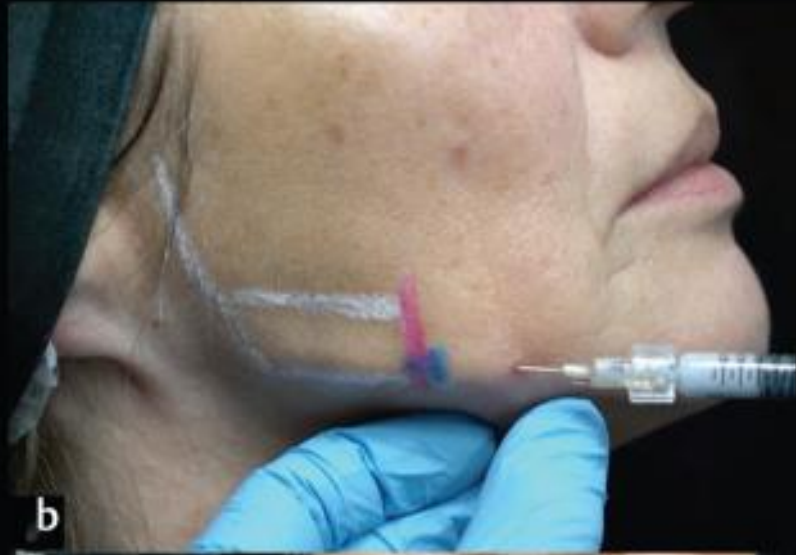




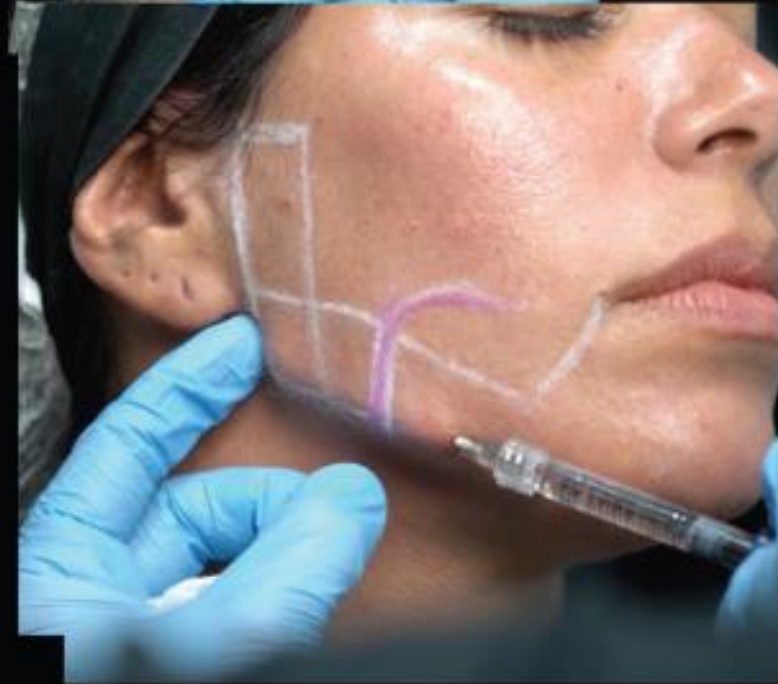


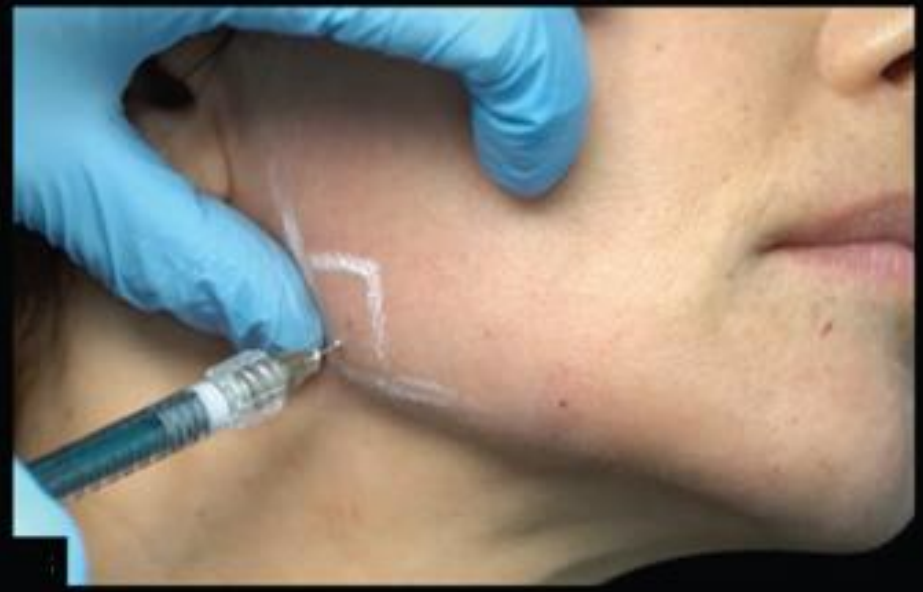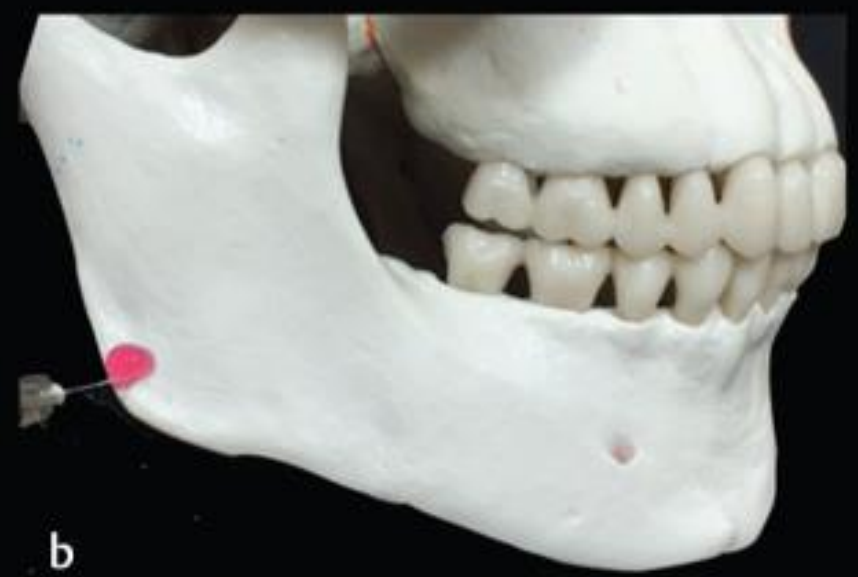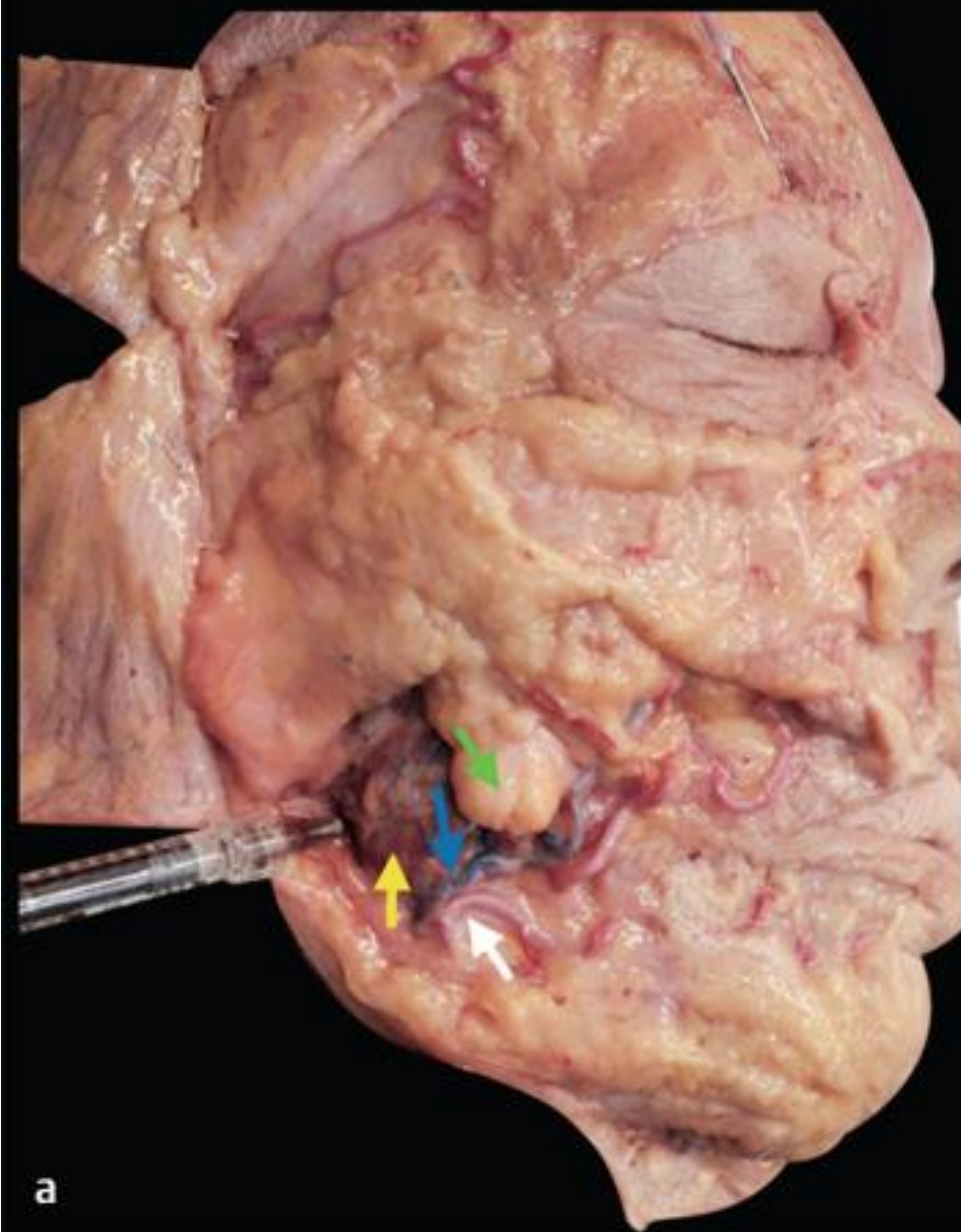
a



b



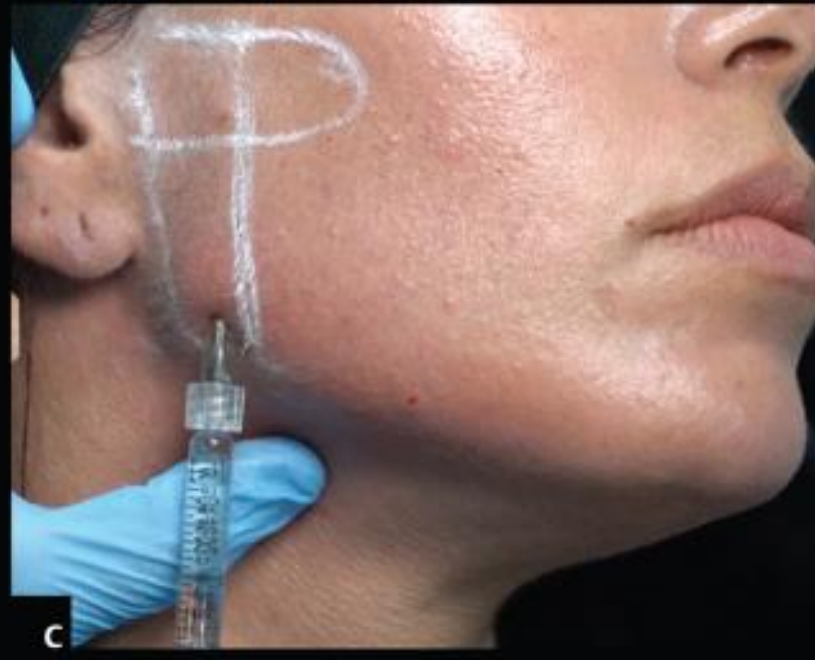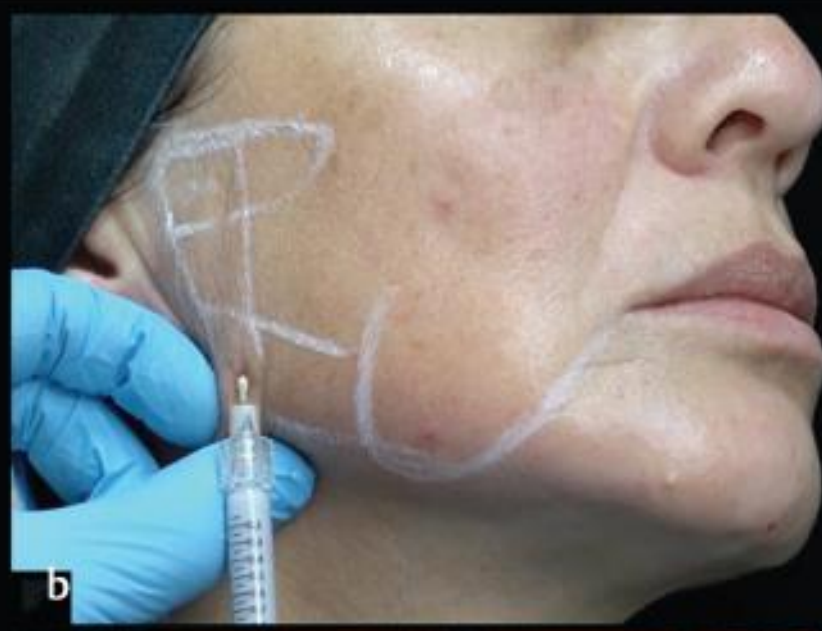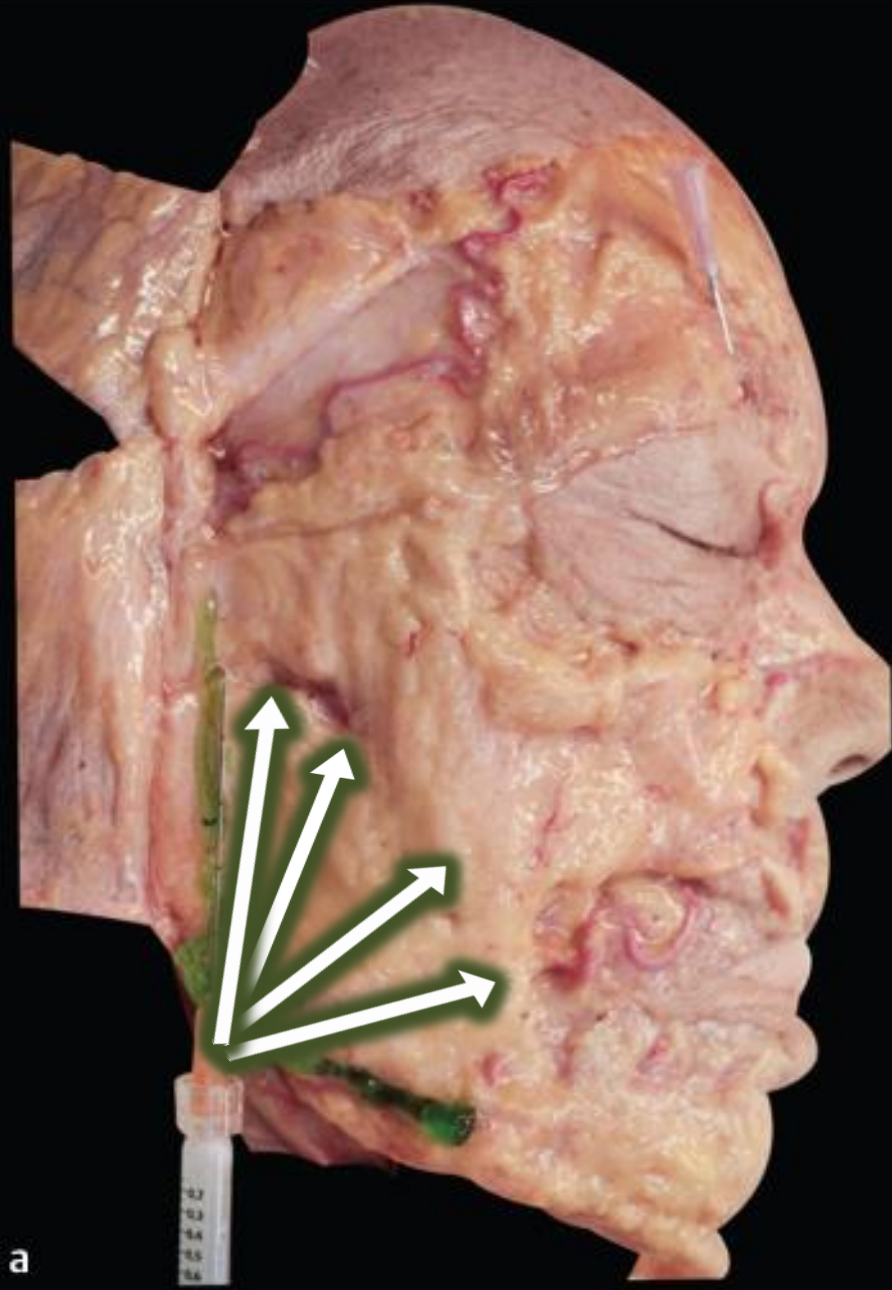
c

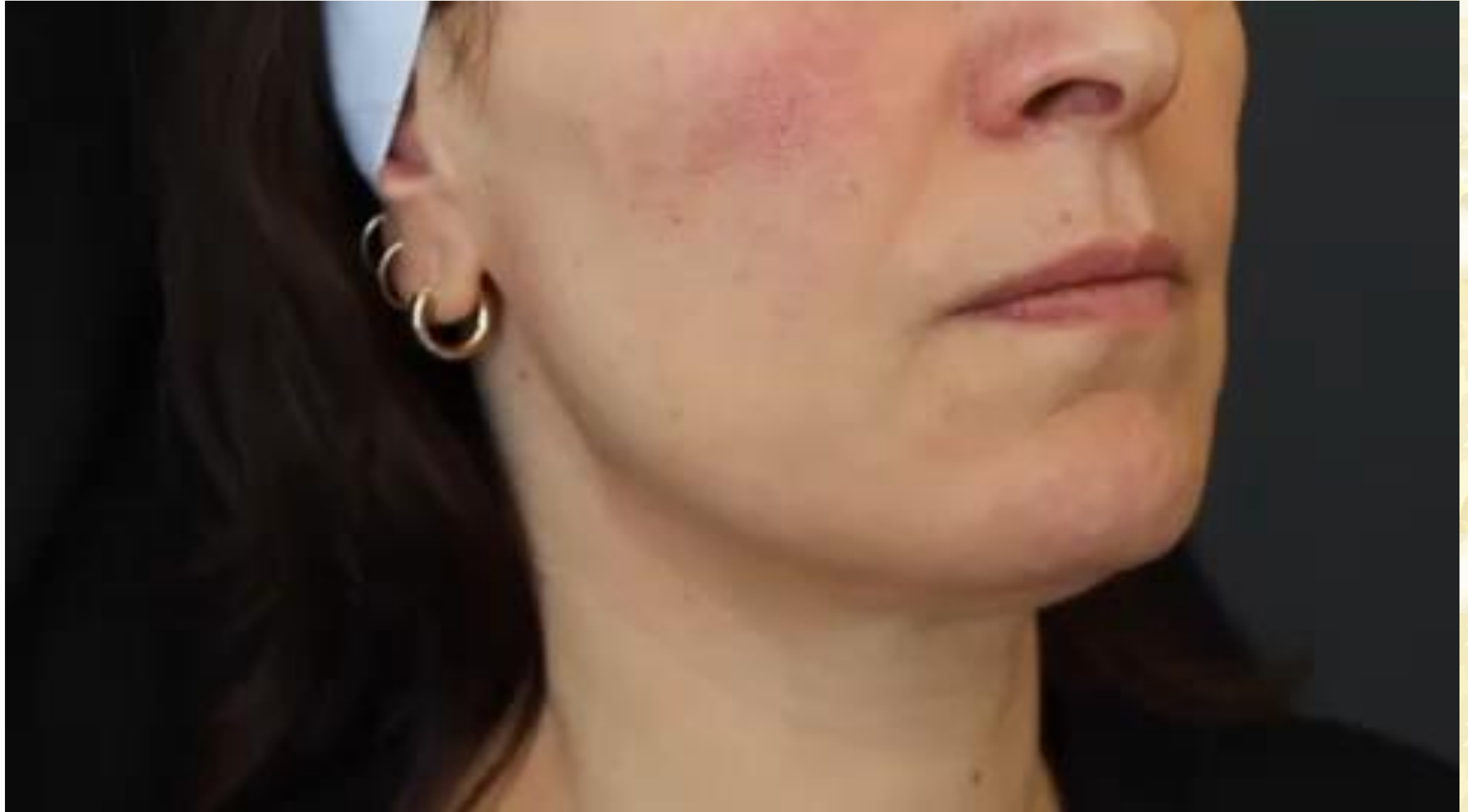

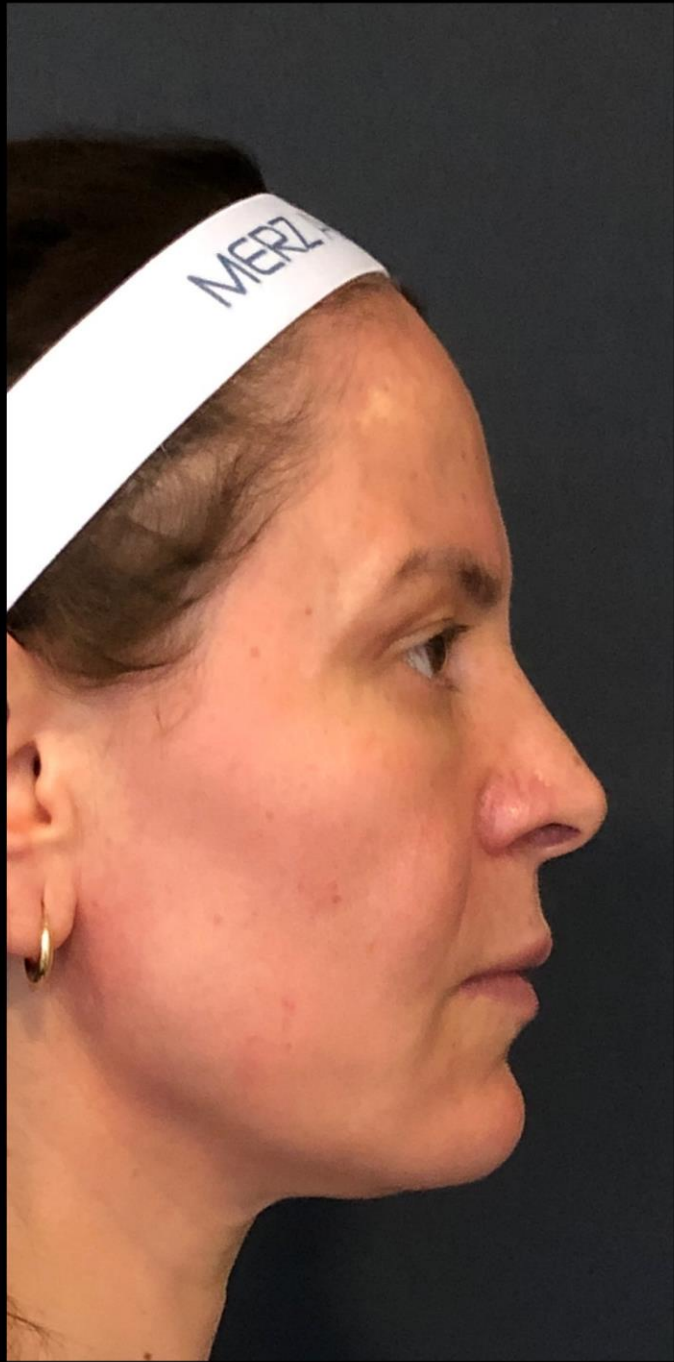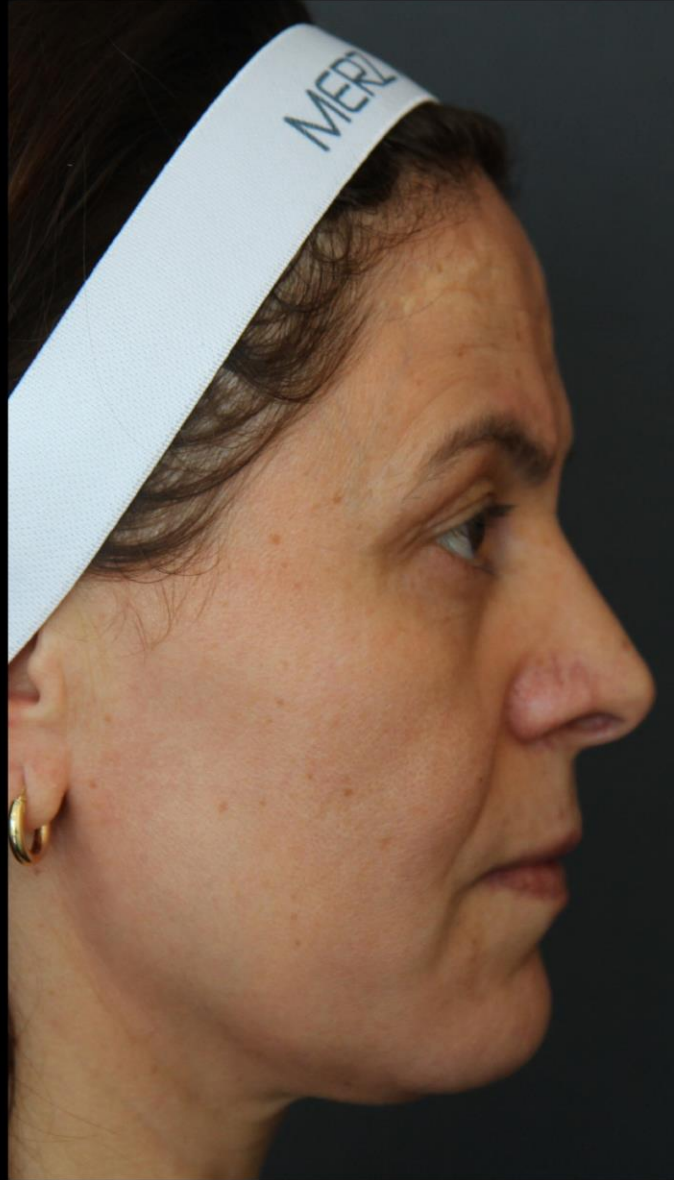a

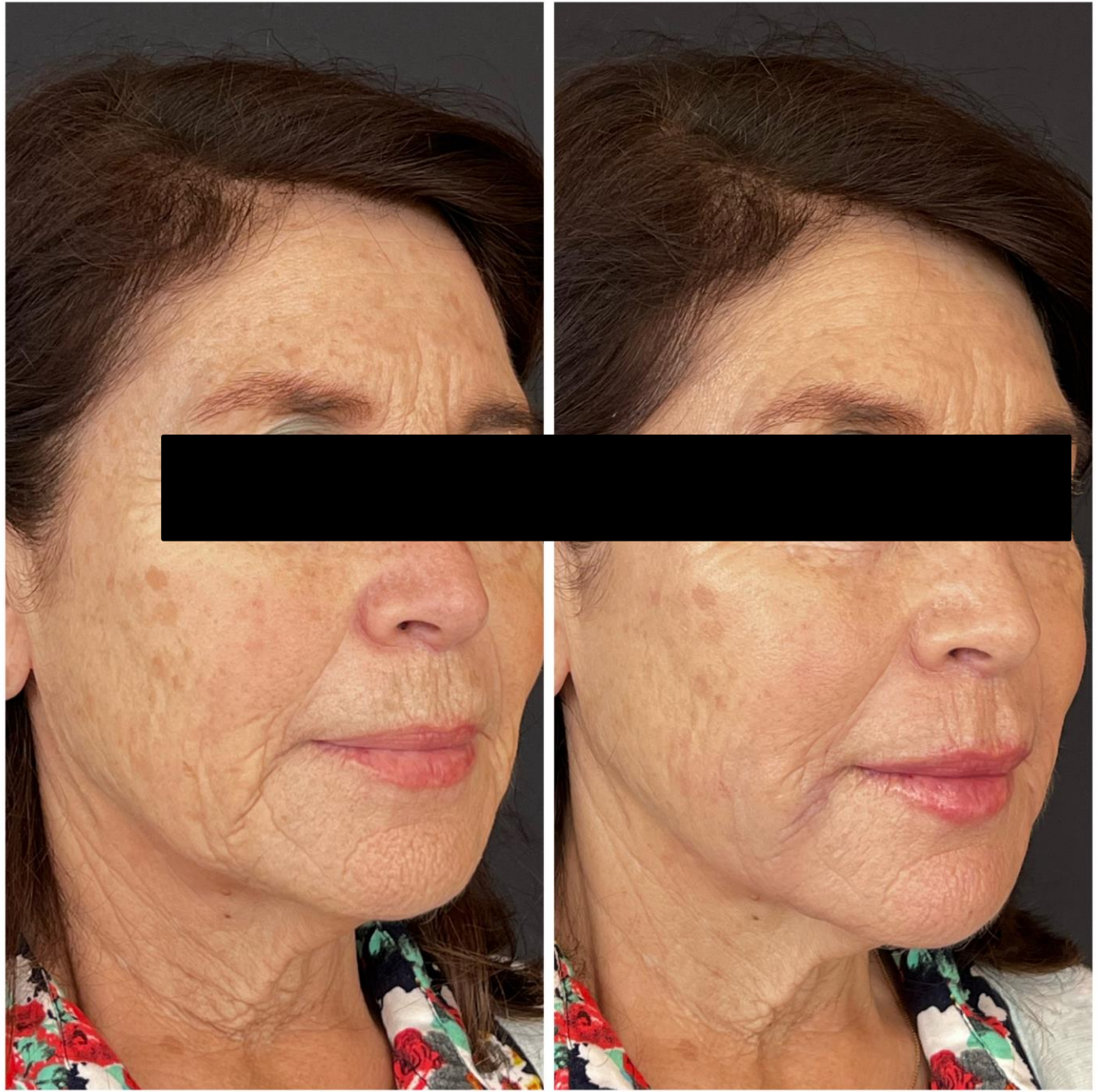b

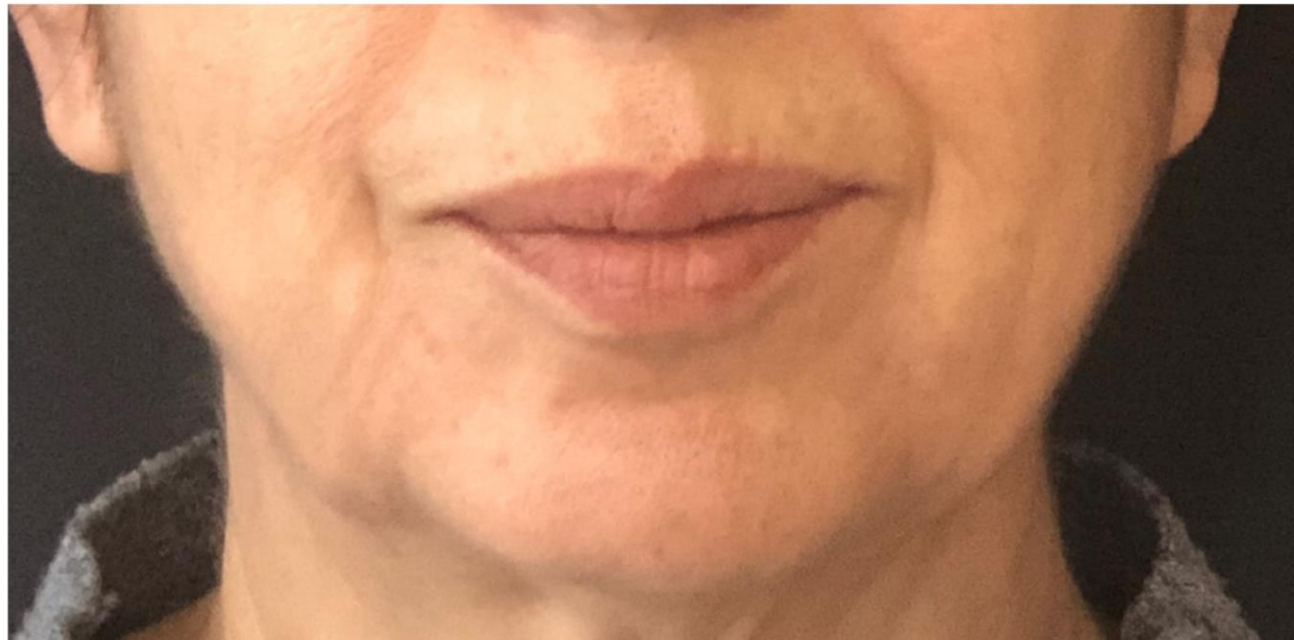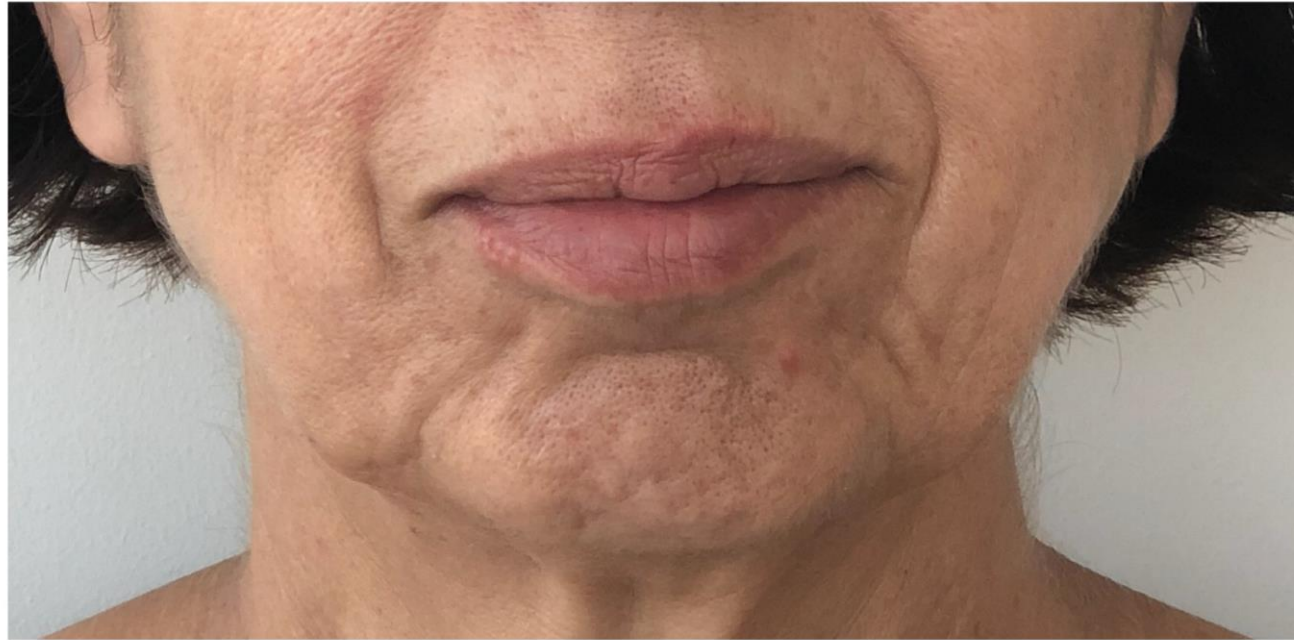c

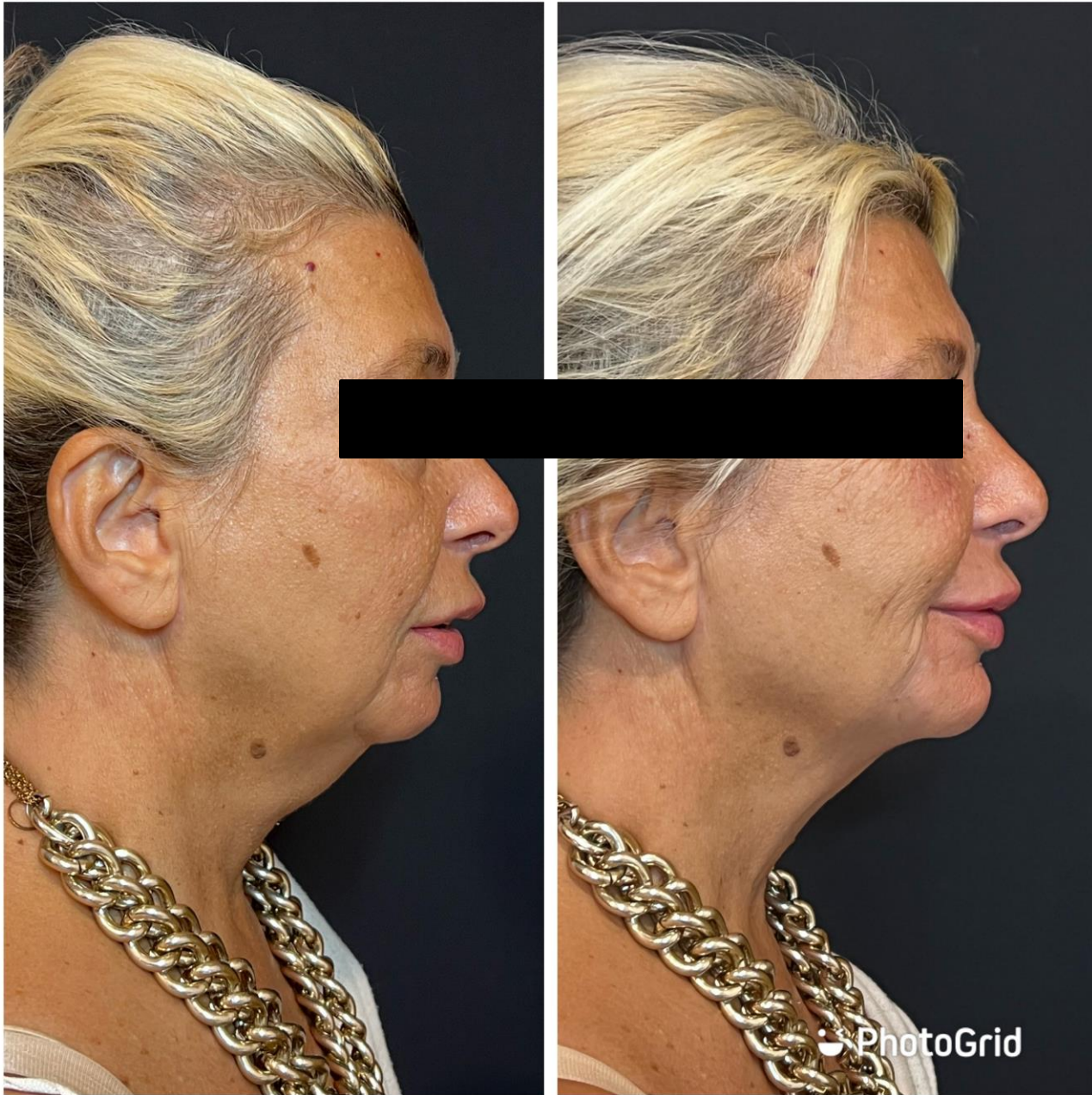


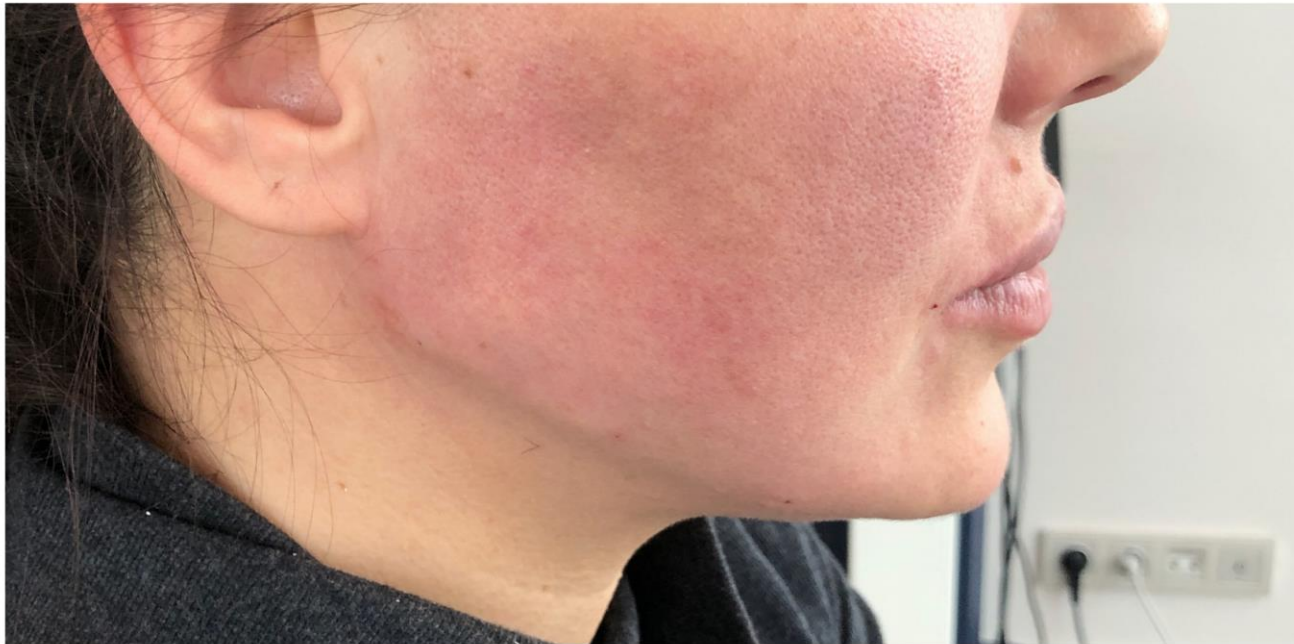
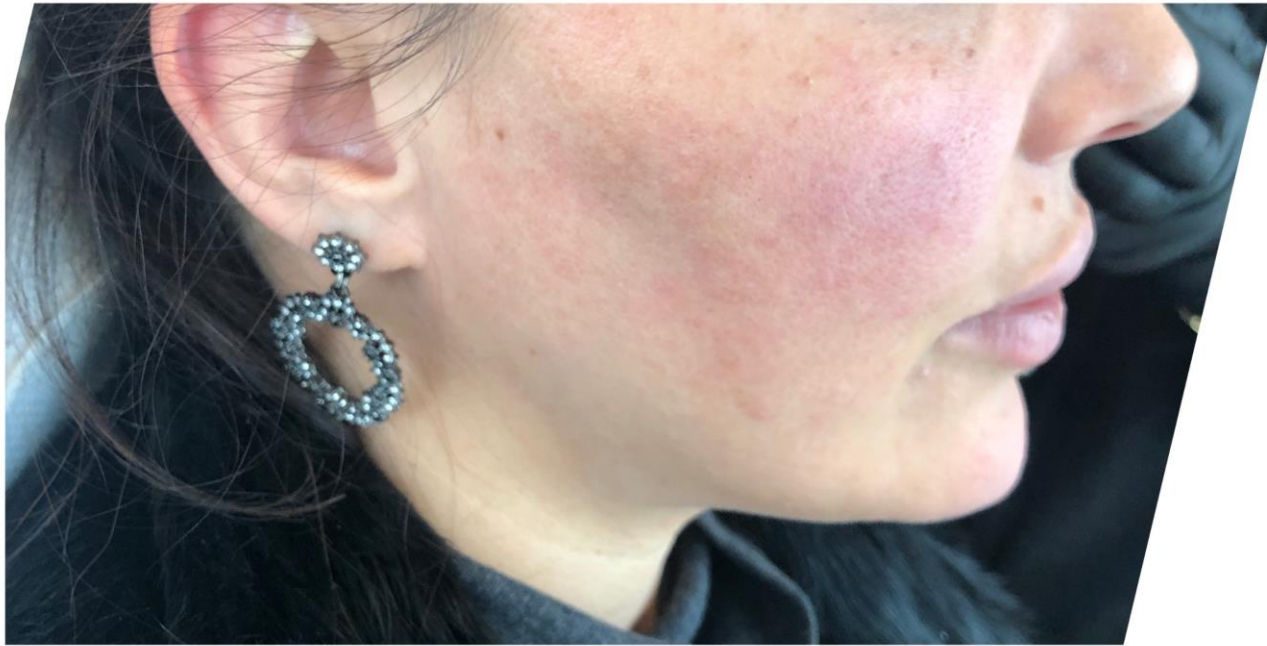


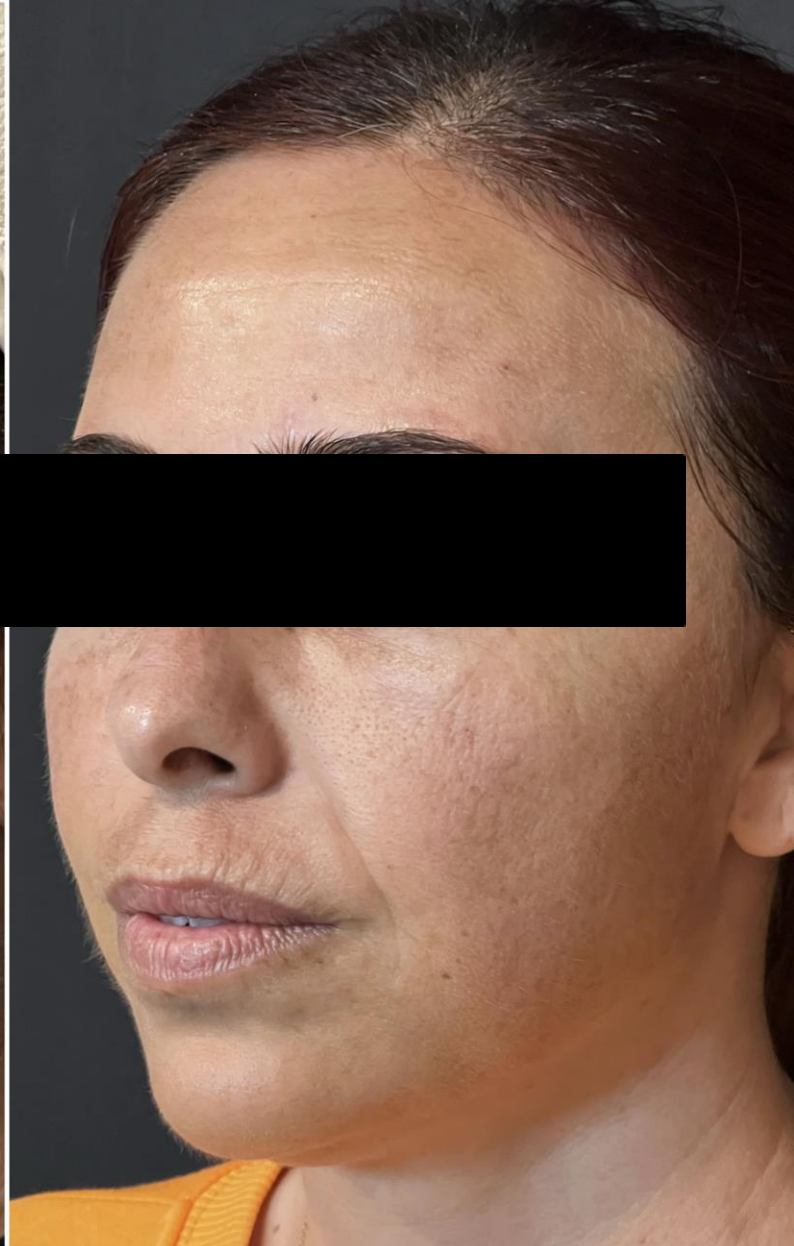
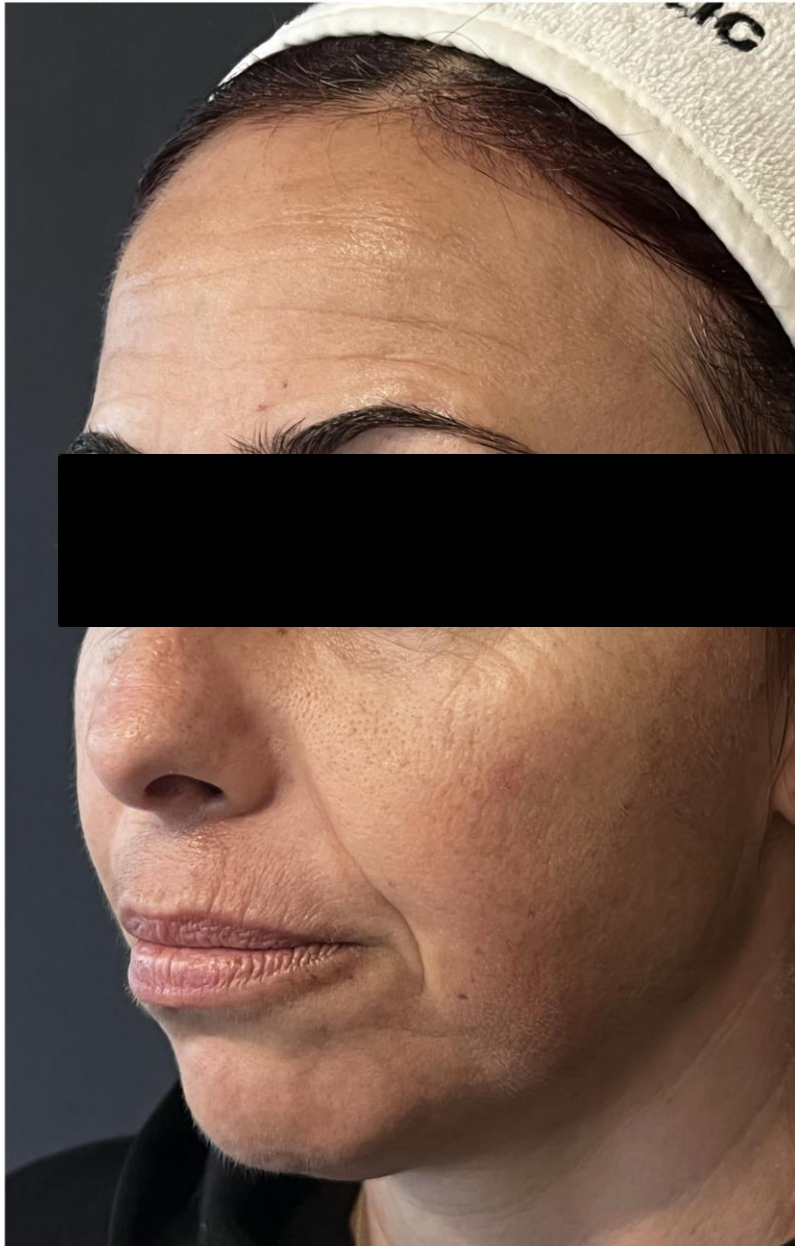


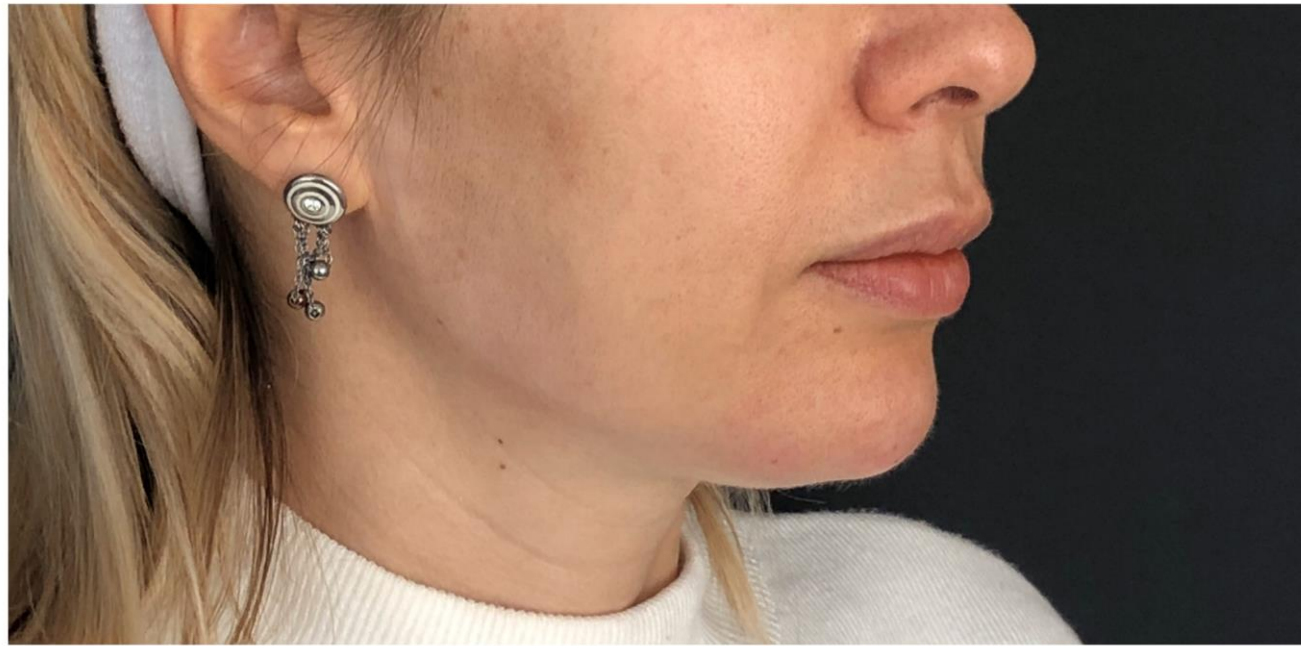
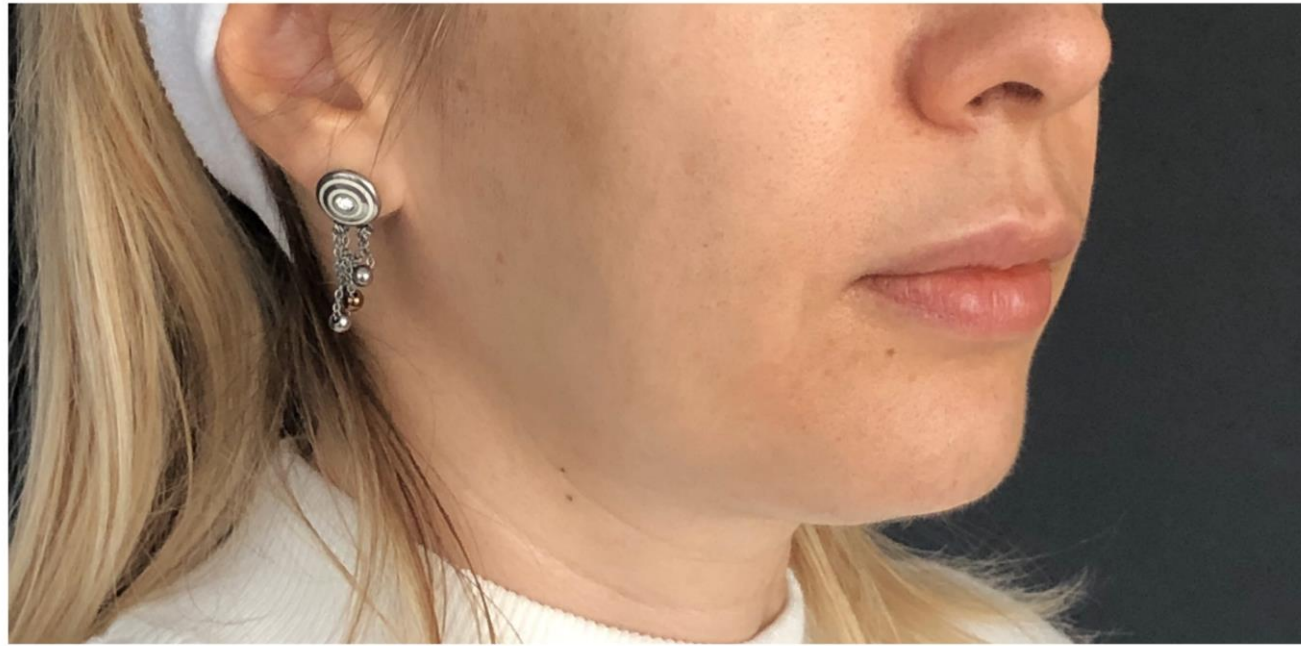

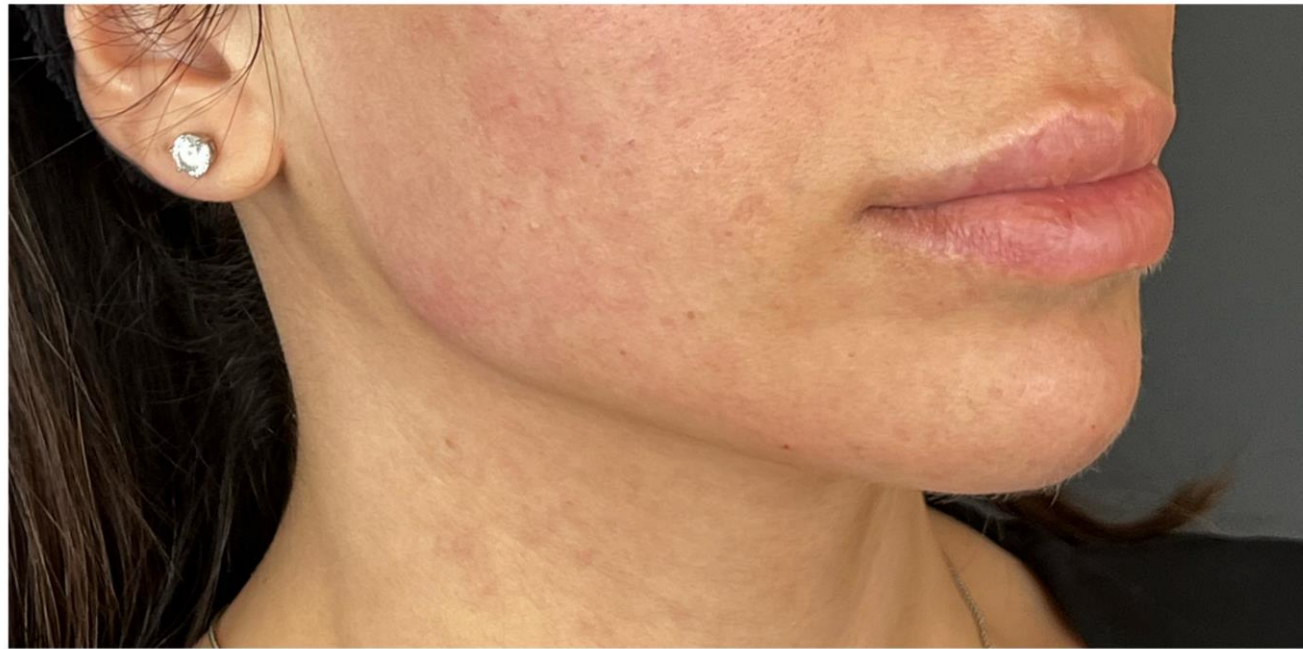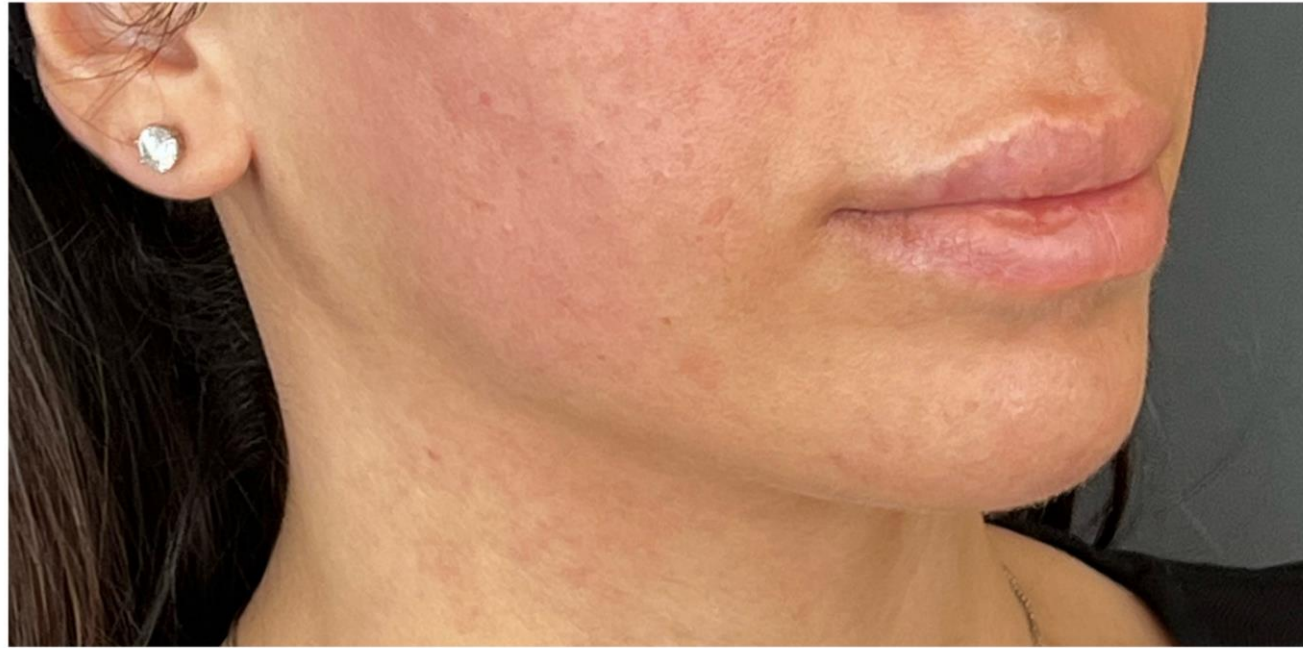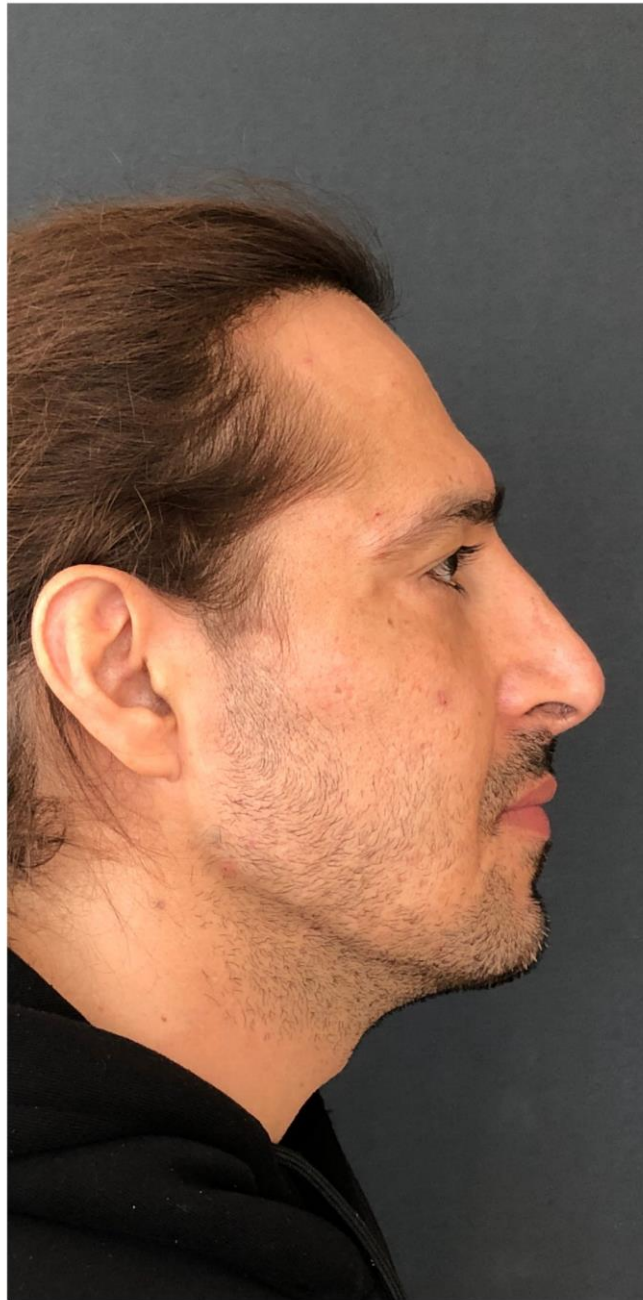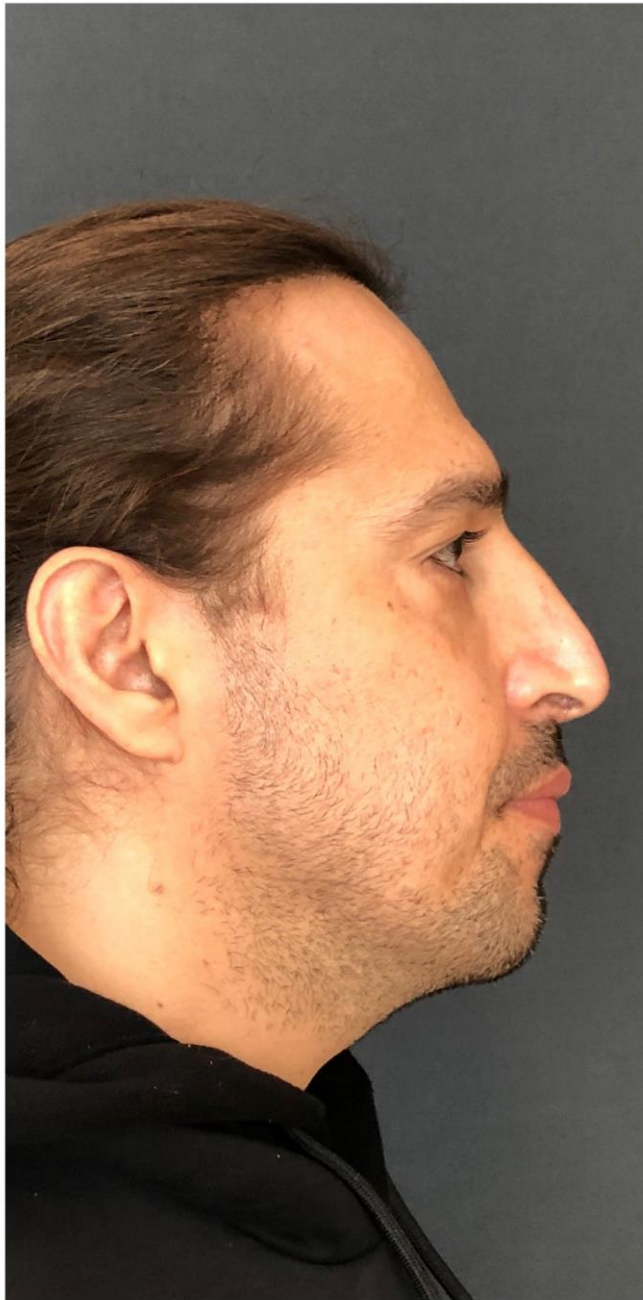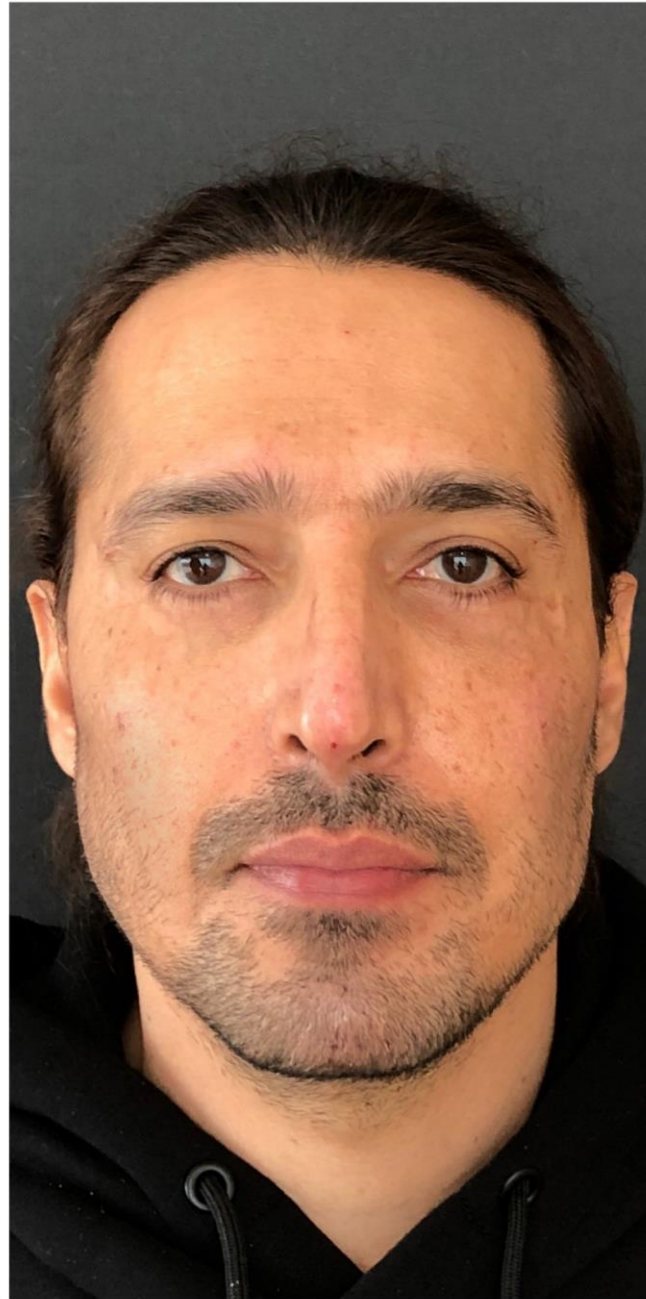
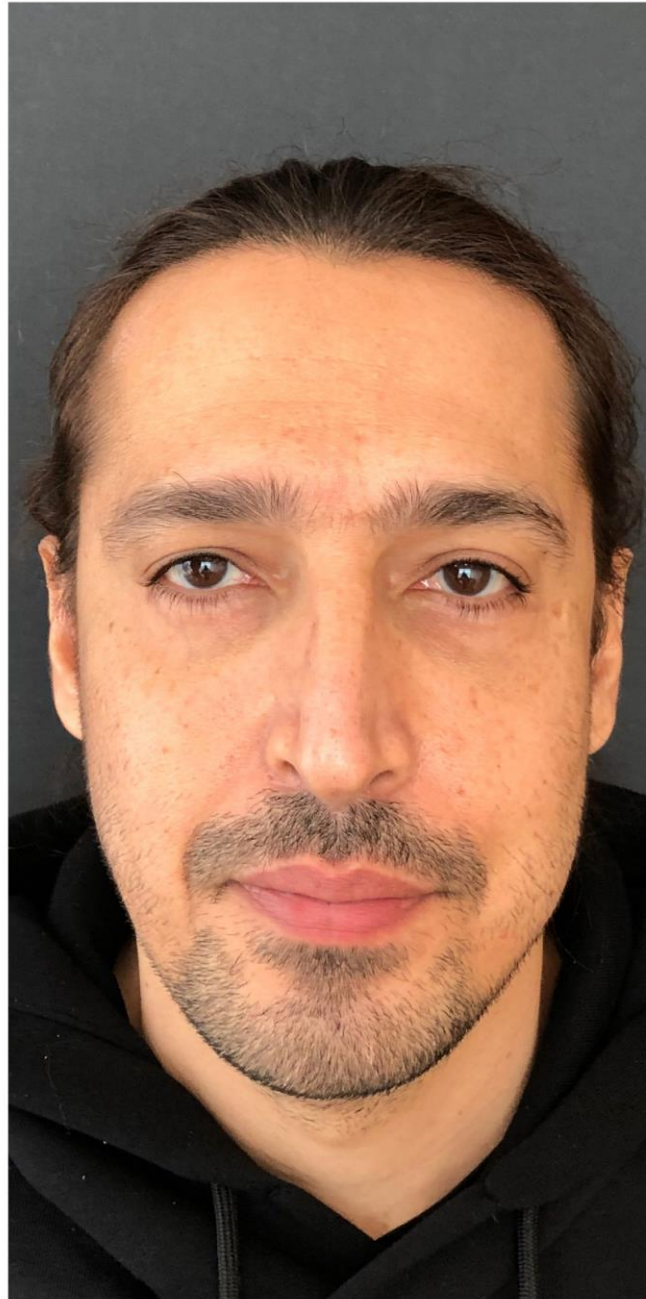













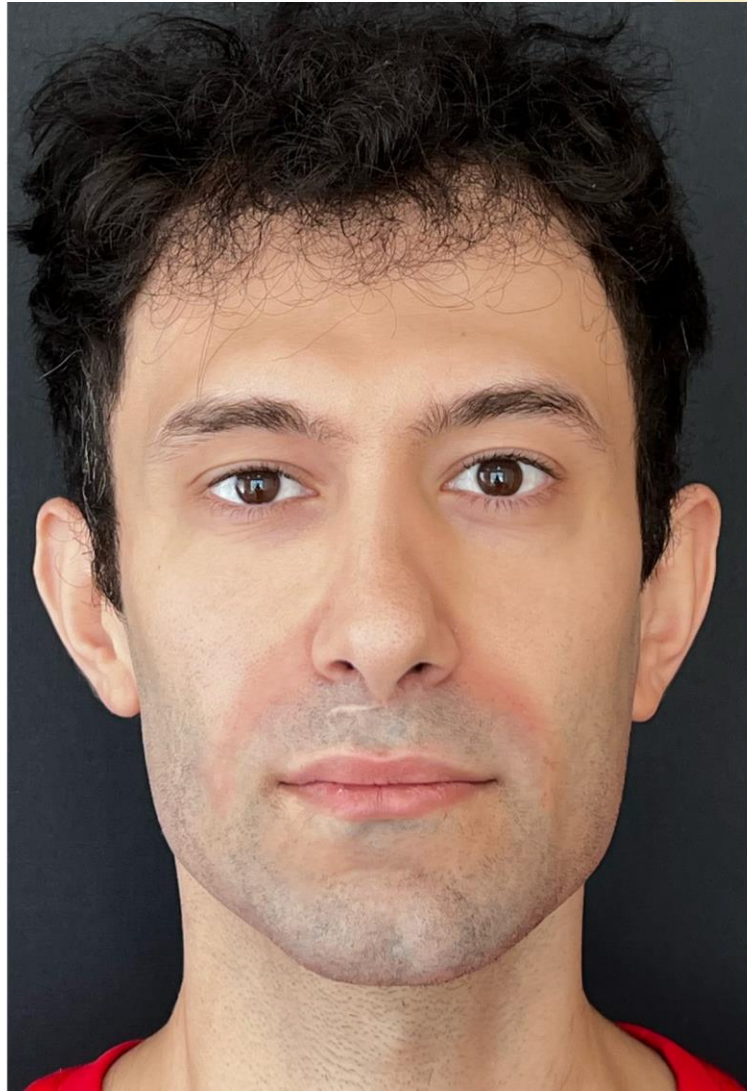


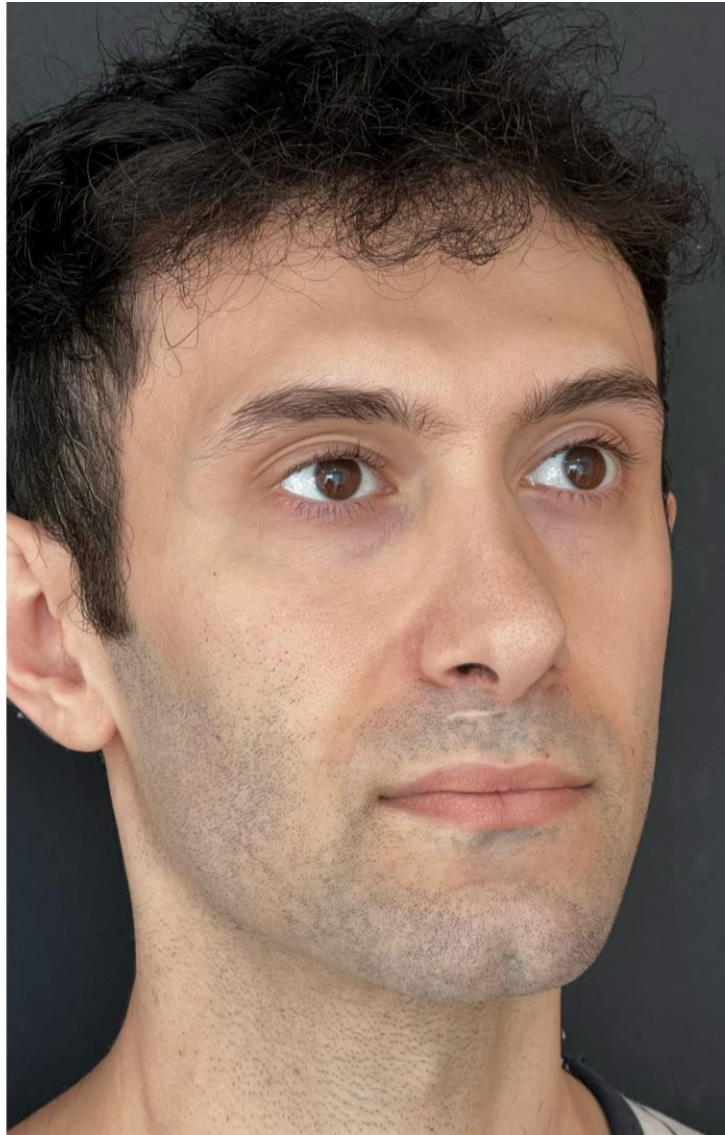









**TEŐEKKÜR
EDERİM**



Dr. DİLEK BAŐARAN
Dermatoloji Uzmanı